

Total Elbow Arthroplasty as Primary Treatment for Distal Humeral Fractures in Elderly Patients*

BY TYSON K. COBB, M.D.†, AND BERNARD F. MORREY, M.D.†, ROCHESTER, MINNESOTA

Investigation performed at the Mayo Clinic, Rochester

ABSTRACT: We retrospectively reviewed the results of primary total elbow arthroplasty for the treatment of an acute fracture of the distal aspect of the humerus in twenty consecutive patients (twenty-one elbows) who had a mean age of seventy-two years (range, forty-eight to ninety-two years) at the time of the injury. The patients were managed between November 1982 and October 1992. The presence of rheumatoid arthritis in nine patients (ten elbows) influenced the choice of treatment. The mean interval between the injury and the total elbow arthroplasty was seven days (range, one to twenty-five days). The mean duration of postoperative hospitalization was seven days (range, four to thirteen days). The mean duration of follow-up was 3.3 years (range, three months to 10.5 years). All patients were followed for a minimum of two years or until the time of death; the duration of follow-up was less than two years for three patients who died. None of the patients were lost to follow-up. Twenty implants were intact at the latest follow-up examination. One patient had a revision total elbow arthroplasty twenty months after the index procedure because of a fracture of the ulnar component sustained in a fall on the outstretched arm.

On the basis of the Mayo elbow performance score, fifteen elbows had an excellent result and five had a good result; there were inadequate data for one elbow. There were no fair or poor results. The mean arc of flexion was 25 to 130 degrees. There was no evidence of loosening on the radiographs. Postoperative complications included fracture of the ulnar component in one patient, ulnar neurapraxia in three, and reflex sympathetic dystrophy in one. The results suggest that total elbow arthroplasty can be an alternative form of treatment of a severely comminuted fracture of the distal aspect of the humerus in older patients even in the presence of rheumatoid arthritis. This procedure is not an alternative to osteosynthesis in younger patients.

Total elbow arthroplasty has been shown to be a viable option for the treatment of post-traumatic deformities of the elbow in carefully selected patients who are more than sixty years old¹⁵. Since 1982, we have

performed total elbow arthroplasty in elderly patients who had a severely comminuted fracture about the elbow. These patients were carefully selected; the procedure was performed only in the absence of any suitable alternative treatment. We analyzed the results to determine the usefulness of total elbow arthroplasty for the treatment of extensively comminuted fractures of the distal aspect of the humerus.

Materials and Methods

Between November 1982 and October 1992, we treated 129 acute fractures of the distal aspect of the humerus in 125 adults. Twenty-one of these fractures (twenty patients) were treated with total elbow arthroplasty (Table I). The specific indications for the total elbow arthroplasty were an extensively comminuted acute fracture of the distal aspect of the humerus in nine patients (ten elbows) who also had destruction of the articular surface secondary to rheumatoid arthritis, and a comminuted intra-articular fracture in eleven patients who were more than sixty-five years old. Five of the eleven fractures in the patients who did not have rheumatoid arthritis were type C3 according to the AO classification system of Müller et al. The contraindications to total elbow arthroplasty were neurological or other injuries that would impair function of the limb, active infection, or a contaminated open fracture. Extension of the fracture into the humeral shaft was not a contraindication, as the distal aspect of the humerus could be shortened, if necessary, and fixation devices are available to stabilize fractures of the shaft.

The mean age of the fifteen women and the five men was seventy-two years (range, forty-eight to ninety-two years), whereas the mean age of the entire group of 125 patients (129 elbows) who were managed because of an acute fracture of the distal aspect of the humerus was forty-nine years (range, twenty-two to ninety-two years). Eleven fractures involved the dominant extremity, and ten involved the non-dominant extremity. The usual mechanism of injury was a minor fall. The comorbid condition of rheumatoid arthritis in nine patients (ten elbows) had a direct influence on the choice of treatment. Rheumatoid arthritis is a disease of joints that usually is treated with replacement arthroplasty. The mean interval between the injury and the total elbow arthroplasty was seven days (range, one to twenty-five days). Treatment before the arthroplasty included

*One or more of the authors have received or will receive benefits for personal or professional use from a commercial party related directly or indirectly to the subject of this article. No funds were received in support of this study.

†Mayo Clinic, 200 First Street, S.W., Rochester, Minnesota 55905.

TABLE I
DATA ON THE TWENTY-ONE ELBOWS (TWENTY PATIENTS) THAT HAD TREATMENT OF AN ACUTE FRACTURE WITH TOTAL ELBOW ARTHROPLASTY

Case	Gender, Age (Yrs.)	Affected Side (Dominant Extremity)	Associated Diagnosis	Time to Total Elbow Arthroplasty (Days)	Complications	Durat. of Follow-up (Yrs.)	Durat. of Postop. Hospitalization (Days)	Arc of Flex./Exten.* (Degrees)	Arc of Pronat./Supinat.* (Degrees)	Patient Satisfied	Pain	Mayo Elbow Performance Score ^{16*} (Points)
1	F, 86	R (R)		2	Pulmonary embolism 1 day postop.	2.5	13	10/125	80/80	Yes	None	100
2	F, 92	L (R)	Osteoporosis	5	Neurapraxia, ulnar nerve; resolved at 3 mos.	2.5	8	20/140	80/90	Yes	None	100
3	F, 68	R (R)	Rheum. arthrit.	4	None	10.5	12	30/110	60/60	Yes	None	95
4	M, 77	L (R)	Rheum. arthrit.	1	None	4 mos. (died)	8	40/130	NR	Yes	None	75
5	F, 70	L (R)		1	Dysesthesias, little finger	3 mos. (died)	8	20/125	70/70	Yes	Mild	85
6	F, 65	R (R)		1	None	3	4	10/130	70/70	Yes	None	100
7	F, 81	L (R)		20	None	5	10	35/135	80/60	Yes	None	100
8	M, 50	L (R)	Rheum. arthrit.	2		4	5	15/130	70/80	Yes	None	100
9	F, 82	L (R)		6	Dysesthesias, little finger	5	5	45/120	70/60	Yes	Mild	75
10	F, 70	R (R)	Rheum. arthrit.	14	Reflex sympathetic dystrophy; resolved at 3 mos.	7	7	30/135	90/90	Yes	None	100
11†	M, 73	R (R)	Rheum. arthrit., osteoporosis	2	None	5	7	20/140	70/70	Yes	None	100
12†	M, 74	L (R)	Rheum. arthrit.	10	None	3	4	25/135	NR	Yes	None	100
13	F, 78	R (R)	Rheum. arthrit.	3	Myocardial infarction intraop.	2	5	30/130	NR	Yes	None	100
14	F, 84	R (R)		1	None	2	7	25/130	NR	Yes	None	100
15	F, 66	L (R)		3	None	10 mos. (died)	5	NR	NR	Yes	None	NR
16	F, 75	R (R)		4	Cerebrovasc. accident intraop.	2.3	11	10/140	NR	Yes	Mild	85
17	M, 66	R (R)	Rheum. arthrit.	7	None	3	5	35/135	65/65	Yes	None	85
18	F, 48	L (R)	Rheum. arthrit.	21	Superficial wound infect.; resolved with postop. antibiotics	2	6	30/130	65/70	Yes	None	100
19	F, 68	L (L)	Rheum. arthrit.	2	None	3	4	20/135	75/75	Yes	None	100
20	M, 80	L (R)		3	Fract. of ulnar component 20 mos. postop.	3.8	7	5/115	80/80	Yes	None	100
21	F, 67	L (L)		25	Fibrous non-union at site of osteot. of olecranon performed during attempted open reduct. & internal fixat. elsewhere	2	5	35/130	80/75	Yes	None	95
Mean				7		3.3	7	25/130	74/73			95

*NR = not recorded.

†Cases 11 and 12 were the same patient.

closed reduction in three elbows, an initial unsuccessful attempt at open reduction and internal fixation in three, and irrigation and débridement in two. Total elbow

arthroplasty was the treatment of choice for these patients; open reduction and internal fixation was not a viable option because of the degree of comminution

and the poor bone stock secondary to osteoporosis and rheumatoid arthritis.

At the Mayo Clinic, data on all patients who have a total elbow arthroplasty are prospectively entered in and updated through a computerized registry. Patients who are unable to return for evaluation are sent a questionnaire that allows us to evaluate their level of satisfaction and function. In addition, they are requested to ask a local orthopaedic surgeon to send radiographs as well as the results of a clinical examination.

None of the patients were lost to follow-up. The mean duration of follow-up was 3.3 years (range, three months to 10.5 years). All patients were followed for a minimum of two years or until the time of death. Since the treatment was generally used for older patients, it was not surprising that three patients died within two years after the operation and two more, by the time of the review.

We used the AO classification system of Müller et al. to describe the type of fracture in relation to comminution. There were two type-B1, five type-B2, five type-C2, and six type-C3 fractures; of the three remaining fractures, one was a comminuted supracondylar fracture and two were comminuted intra-articular fractures of the proximal aspect of the ulna. Two of three fractures that were type-I open injuries according to the system of Gustilo and Anderson were treated with irrigation and débridement three days before the replacement arthroplasty.

The design and modifications of the Coonrad-Morrey total elbow implant, used in all patients, were described in a previous report¹⁵. Initially, we used an operative technique that was described previously¹³, but we modified the approach in 1986. All of the implants were inserted with cement. Two sizes of implants — small and standard — were used, and three lengths of humeral components — ten, fifteen, and twenty centimeters — were available for each. A small implant was used in fifteen elbows and a standard implant was used in six.

The range of motion, including the arc of flexion-extension and pronation-supination, was measured with a hand-held goniometer. Eighteen patients were clinically examined by us; the data for the remaining two patients were obtained from the local orthopaedist who had evaluated them. Stability of the elbow was assessed on the basis of the history and the physical examination. Radiographs were made for all patients. The most recent radiographs were evaluated to determine the quality of the fixation and the presence of radiolucent lines. Sequential radiographs were made only for patients who had a radiolucent line, to determine if the process was progressive. Subjective evaluation included information on the patient's level of satisfaction; the amount of pain (none, mild, moderate, or severe); and the ability to perform self-care activities, such as toileting, grooming, dressing, and feeding. The Mayo elbow

performance score¹⁶ was used to assess the over-all effectiveness of treatment. This score is based on a 100-point scale, with a maximum score of 45 points for the category of pain; 25 points, for function; 20 points, for motion; and 10 points, for stability. Adequate information for this index was available for twenty elbows; for one elbow (Case 15), these data had not been recorded. The result was considered excellent if the score was 90 points or more, good if the score was 75 to 89 points, fair if the score was 60 to 74 points, and poor if the score was less than 60 points.

Operative Technique

A posterior midline incision was used, and the ulnar nerve was identified and freed from the fractured epicondyle. The recommended operative technique includes a triceps-sparing approach, which is accomplished by reflecting the triceps attachment and the periosteum in continuity as described by Bryan and Morrey. Alternatively, the triceps insertion can be left intact, and medial and lateral incisions can be used to expose the site of the fracture and the elbow as described for total elbow arthroplasty in patients who have a non-union of the distal aspect of the humerus¹⁴. All soft tissues are released from the bone fragments, which then are excised.

The remainder of the technique was described previously¹³. The humerus is delivered from the lateral margin of the triceps and is prepared for the humeral component. Rotation of the forearm allows the proximal aspect of the ulnar canal to be identified and prepared for the implant. An injection system is used to fill the canal with bone cement. The ulnar and humeral components are inserted and coupled without difficulty, as the distal aspect of the humerus has been resected. We have not found it necessary to use custom-made implants.

Compression dressings and elevation of the extremity are recommended for two to three days, followed by gentle range-of-motion exercises as tolerated. Formal physical-therapy sessions generally are not necessary.

Results

One patient (Case 20) had a revision total elbow arthroplasty twenty months after the index procedure because of a fracture of the ulnar component sustained in a fall on the outstretched arm. All of the remaining implants were in place and functioning at the time of the latest follow-up evaluation. The mean duration of postoperative hospitalization was seven days (range, four to thirteen days); the longest stay was that of a patient in whom a pulmonary embolism developed. The mean duration of stay at the acute level of care was ten days for the three patients who were managed before 1988 and seven days for the remaining seventeen patients. These differences are related more to changing trends with regard to length of stay at the acute level of

TABLE II
MAYO ELBOW PERFORMANCE SCORE¹⁶

Function	No. of Elbows*	Mean Score (Points)
Pain (max., 45 points)		
None (45 points)	17 (85%)	
Mild (30 points)	3 (15%)	
Moderate (15 points)	0	
Severe (0 points)	0	
Mean		43
Range of motion (max., 20 points)		
Arc > 100 degrees (20 points)	16 (80%)	
Arc 50 to 100 degrees (15 points)	4 (20%)	
Arc < 50 degrees (5 points)	0	
Mean		19
Stability (max., 10 points)		
Stable (10 points)	20 (100%)	
Moderately unstable (5 points)	0	
Grossly unstable (0 points)	0	
Mean		10
Function (max., 25 points)		
Able to comb hair (5 points)	18 (90%)	
Able to feed oneself (5 points)	20 (100%)	
Able to perform personal hygiene tasks (5 points)	19 (95%)	
Able to put on shirt (5 points)	18 (90%)	
Able to put on shoes (5 points)	18 (90%)	
Mean		23
Mean total (max., 100 points)		95

*The data are given for twenty elbows (nineteen patients) because there was inadequate information for one elbow (one patient).

care than to differences in postoperative management. Currently, patients are discharged on or about the fifth postoperative day.

All patients were satisfied with the functional result. Three patients reported mild pain postoperatively; one had pain with activity, and the other two had pain associated with dysesthesias of the ulnar nerve. Functional data with regard to toileting, grooming, and feeding activities were available for nineteen patients (twenty elbows). All patients were able to feed themselves. One patient who had severe dementia and disability lived in an extended-care facility and received custodial-level care for all of her needs except eating. Several patients who had rheumatoid arthritis had difficulty tying their shoes. One patient who had severe rheumatoid arthritis was unable to comb his hair or to put on his shirt or shoes because of severe involvement of the hands.

All patients had a flexion contracture of the elbow, which ranged from 5 to 45 degrees; additional flexion ranged from 115 to 140 degrees. The mean arc of flexion-extension was 25 to 130 degrees. The mean arc of pronation-supination was 74 to 73 degrees. All elbows were stable at the latest follow-up examination.

Radiolucent lines were seen on the follow-up radiographs of three elbows; they had been present immediately after the operation and were incomplete and non-progressive. There was no evidence of loosening in

any patient. Severe osteoporosis was common but did not appear to influence the functional result.

Mayo elbow performance score: The Mayo elbow performance score was calculated for twenty elbows (nineteen elbows); there were inadequate data for one elbow (one patient [Case 15]). The mean score for pain was 43 (range, 30 to 45) of a possible 45 points (Table II). Sixteen elbows had a functional arc of motion, and the mean score for motion was 19 (of a possible 20) points. All elbows received the maximum score of 10 points for stability. All nineteen patients (twenty elbows) received the maximum score of 5 points for the ability to feed themselves; eighteen patients (95 per cent [nineteen] of the elbows), for performing personal hygiene tasks independently; and seventeen patients (90 per cent [eighteen] of the elbows), for dressing and combing their hair independently. The result was rated as excellent for fifteen elbows and as good for five. There were no fair or poor results.

Complications: The intraoperative complications included a myocardial infarction in one patient and a stroke in another. The postoperative complications included a pulmonary embolism on the first postoperative day in one patient, a superficial wound infection that resolved after oral administration of antibiotics in one, fracture of the ulnar component twenty months postoperatively in one, neurapraxia of the ulnar nerve in one, dysesthesias along the ulnar nerve distribution in the hand in two, and reflex sympathetic dystrophy in one patient. One patient had a non-union at the site of an osteotomy of the olecranon that had been performed during an attempted open reduction and internal fixation at another institution.

Discussion

The treatment of comminuted fractures of the distal aspect of the humerus in elderly patients is technically difficult, is associated with a high rate of complications, and generally yields poor results²⁴. John et al. reported the results of operative treatment of fractures of the distal aspect of the humerus in forty-nine elderly patients. At a mean of eighteen months, ten patients had a fair or poor result and seventeen had persistent pain. The mean length of stay in the hospital was twenty days (range, six to 115 days). Complications included fracture of the plate or screws in four patients, symptoms related to the ulnar nerve in six, and non-union at the site of the osteotomy of the olecranon in two. Motion was excellent (range, -15 to 130 degrees) in fifteen patients, good (range, -30 to 120 degrees) in twenty-five, fair (range, -40 to 90 degrees) in seven, and poor in two. Ten patients assessed the result as fair or poor⁸. Helfet and Schmeling reviewed the results of nine published studies and reported less-than-good results in 25 per cent of the patients. (The actual number of patients reported on in these studies was not included in the review.) The complications included heterotopic

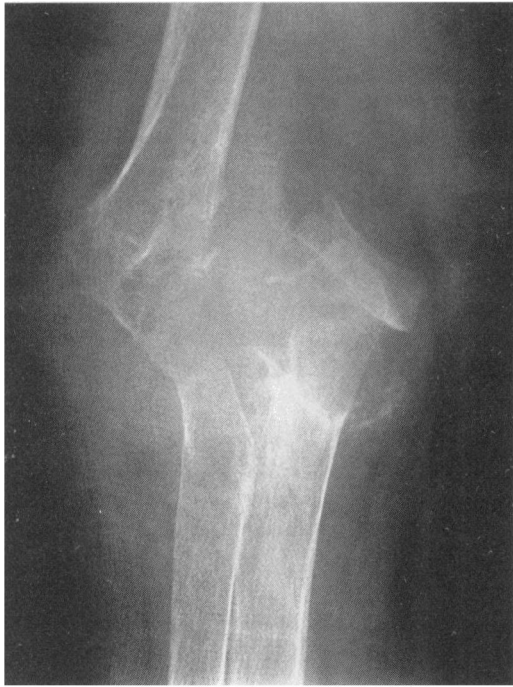

FIG. 1-A

Figs. 1-A, 1-B, and 1-C: Case 11. Radiographs of a seventy-three-year-old man who fell and sustained a severe intra-articular fracture of the elbow. He had rheumatoid arthritis and severe osteoporosis.

Fig. 1-A: Anteroposterior radiograph showing the fracture.

ossification in 3 to 30 per cent of the patients, infection in 3 to 7 per cent, ulnar nerve palsy in 7 to 15 per cent, failure of fixation in 5 to 15 per cent, and non-union in 1 to 11 per cent. These reports of a high rate of complications, residual pain, and limited function in a large percentage of patients raise questions about the effectiveness of osteosynthesis in elderly patients and emphasize the need for better methods of treatment.

The use of total hip arthroplasty in elderly patients who have a fracture of the femoral neck is fairly well accepted. Consequently, replacement arthroplasty has been considered for other major joints when a fracture of a long bone is adjacent to the joint or is intra-articular or when there is extensive comminution of the fracture. Long-term follow-up results of total elbow arthroplasty for an acute fracture of the distal aspect of the humerus are not available, in part because of the increased mean age of these patients. Only five patients in the current series were followed for five years or more, and only one patient was followed for more than ten years. Total elbow replacement arthroplasty has not been considered as an option for the treatment of comminuted fractures of the distal aspect of the humerus, primarily because the outcome is not predictable after total elbow arthroplasty in general. However, we believe that, on the basis of our results with currently available systems, total elbow arthroplasty has a role in the treatment of some fractures of the distal aspect of the humerus.

Total elbow arthroplasty has undergone numerous changes in the past twenty years, and the marked improvement in the results has been due to improvements in the design of the implants, the operative technique, and the selection of patients^{1,10,12,13,18}. The indications for total elbow arthroplasty have likewise changed, and good results have been reported for carefully selected patients who have post-traumatic osteoarthritis¹³. Joint-replacement arthroplasty also has been used to treat non-unions but not acute fractures^{5,14}. Figgie et al. reported an excellent or good result for eight of fourteen patients and seven postoperative complications in five

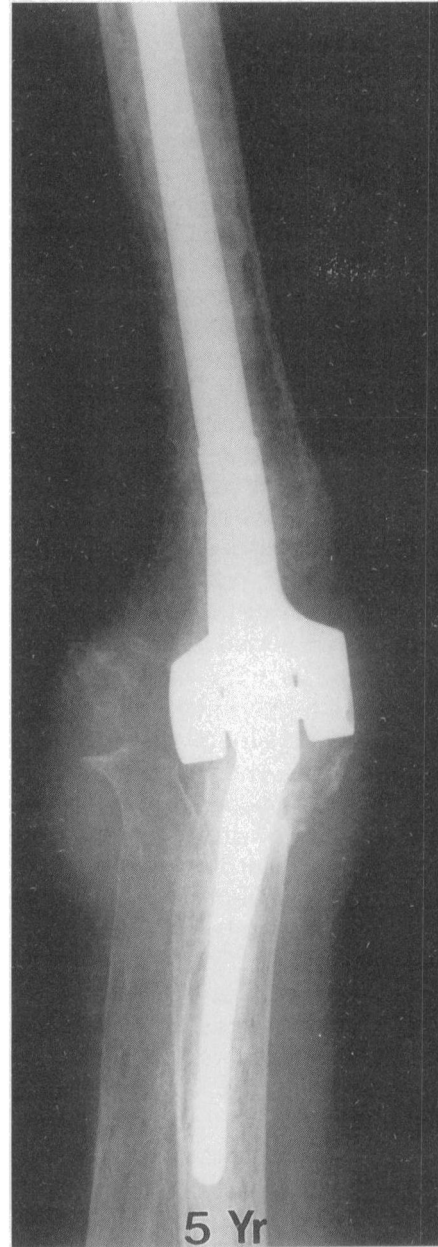

FIG. 1-B

Figs. 1-B and 1-C: Radiographs made five years after the total elbow arthroplasty. The patient had a painless arc of flexion-extension from 20 to 140 degrees.

Fig. 1-B: Anteroposterior radiograph.

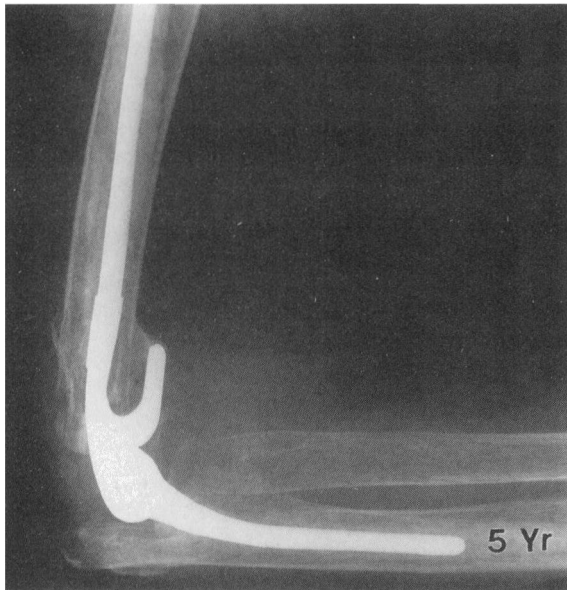


FIG. 1-C
Lateral radiograph.

elbows in association with treatment of a non-union about the elbow. The senior one of us (B. F. M.) has performed total elbow arthroplasty primarily for patients who are more than sixty-five years old and have severe articular involvement and comminution. Success rates of 86 per cent¹⁴ and 85 per cent¹¹ have been noted after total elbow arthroplasty for the treatment of non-union of the distal aspect of the humerus and for the treatment of post-traumatic osteoarthritis, respectively. The alternative of open reduction and internal fixation, a technically demanding procedure, often results in osteoarthritis and pain⁹, and secondary procedures usually are needed subsequently⁷.

The presence of rheumatoid arthritis was an important selection factor for nine patients (ten elbows) in the current series. The long-term result in all nine patients

was satisfactory (Figs. 1-A, 1-B, and 1-C). An arc of flexion of the elbow from 30 to 130 degrees has been shown to be adequate for activities of daily living¹⁷; in the present study, the mean final arc of flexion was 25 to 130 degrees. Seventeen patients (eighteen elbows) were able to feed and groom themselves and to perform tasks related to personal hygiene. Two of three patients who had difficulty with these activities had severe deformity of the hands secondary to rheumatoid arthritis. The third patient had severe dementia and lived in an extended-care facility, where she needed custodial-level care.

The indications for replacement arthroplasty as the primary treatment of extensively comminuted intra-articular fractures of the distal aspect of the humerus in elderly patients are strengthened because of the unreliable results and the high rate of complications of open reduction and internal fixation, especially in patients who have rheumatoid arthritis. Furthermore, the operative and hospital costs of open fixation and those of joint replacement are virtually identical at our institution; the difference is less than 1 per cent. The procedure is relatively simple as compared with open reduction and internal fixation of a severely comminuted fracture⁹. However, experience with total elbow arthroplasty should be considered a prerequisite for a surgeon performing the operation. Our recommendations should not be misinterpreted to suggest that we support the use of total elbow arthroplasty rather than open reduction and internal fixation in patients who have an acute fracture of the distal aspect of the humerus. However, total elbow arthroplasty is an option when adequate fixation of a fracture in an elderly patient is difficult because of comminution and poor-quality bone. The fact that only twenty-one procedures were performed during an eleven-year period emphasizes the strict criteria for selection that were used by the senior one of us.

References

1. Barr, J. S., and Eaton, R. G.: Elbow reconstruction with a new prosthesis to replace the distal end of the humerus. A case report. *J. Bone and Joint Surg.*, 47-A: 1408-1413, Oct. 1965.
2. Bigliani, L. U.; Flatow, E. L.; and Pollock, R. G.: Fractures of the proximal humerus. In *Rockwood and Green's Fractures in Adults*, edited by C. A. Rockwood, Jr., D. P. Green, R. W. Bucholz, and J. D. Heckman. Ed. 4, vol. 1, p. 1075. Philadelphia, Lippincott-Raven, 1996.
3. Bryan, R. S., and Morrey, B. F.: Extensive posterior exposure of the elbow. A triceps-sparing approach. *Clin. Orthop.*, 166: 188-192, 1982.
4. DeLee, J. C.: Fractures and dislocations of the hip. In *Rockwood and Green's Fractures in Adults*, edited by C. A. Rockwood, Jr., D. P. Green, R. W. Bucholz, and J. D. Heckman. Ed. 4, vol. 2, p. 1687. Philadelphia, Lippincott-Raven, 1996.
5. Figgie, M. P.; Inglis, A. E.; Mow, C. S.; and Figgie, H. E., III: Salvage of non-union of supracondylar fracture of the humerus by total elbow arthroplasty. *J. Bone and Joint Surg.*, 71-A: 1058-1065, Aug. 1989.
6. Gustilo, R. B., and Anderson, J. T.: Prevention of infection in the treatment of one thousand and twenty-five open fractures of long bones: retrospective and prospective analyses. *J. Bone and Joint Surg.*, 58-A: 453-458, June 1976.
7. Helfet, D. L., and Schmelting, G. J.: Bicondylar intraarticular fractures of the distal humerus in adults. *Clin. Orthop.*, 292: 26-36, 1993.
8. John, H.; Rosso, R.; Neff, U.; Bodoky, A.; Regazzoni, P.; and Harder, F.: Operative treatment of distal humeral fractures in the elderly. *J. Bone and Joint Surg.*, 76-B(5): 793-796, 1994.
9. Jupiter, J. B.; Neff, U.; Holzach, P.; and Allgöwer, M.: Intercondylar fractures of the humerus. An operative approach. *J. Bone and Joint Surg.*, 67-A: 226-239, Feb. 1985.
10. Morrey, B. F.: Indications and patient selection. In *Joint Replacement Arthroplasty*, pp. 275-291. New York, Churchill Livingstone, 1991.
11. Morrey, B. F.: Unpublished data.
12. Morrey, B. F., and Adams, R. A.: Semiconstrained arthroplasty for the treatment of rheumatoid arthritis of the elbow. *J. Bone and Joint Surg.*, 74-A: 479-490, April 1992.

13. **Morrey, B. F., and Adams, R. A.:** Semiconstrained elbow replacement arthroplasty. Rationale, technique, and results. In *The Elbow and Its Disorders*, edited by B. F. Morrey. Ed. 2, pp. 648-664. Philadelphia, W. B. Saunders, 1993.
14. **Morrey, B. F., and Adams, R. A.:** Semiconstrained elbow replacement for distal humeral nonunion. *J. Bone and Joint Surg.*, 77-B(1): 67-72, 1995.
15. **Morrey, B. F.; Adams, R. A.; and Bryan, R. S.:** Total replacement for post-traumatic arthritis of the elbow. *J. Bone and Joint Surg.*, 73-B(4): 607-612, 1991.
16. **Morrey, B. F.; An, K. N.; and Chao, E. Y. S.:** Functional evaluation of the elbow. In *The Elbow and Its Disorders*, edited by B. F. Morrey. Ed. 2, pp. 86-89. Philadelphia, W. B. Saunders, 1993.
17. **Morrey, B. F.; Askew, L. J.; An, K. N.; and Chao, E. Y.:** A biomechanical study of normal functional elbow motion. *J. Bone and Joint Surg.*, 63-A: 872-877, July 1981.
18. **Morrey, B. F.; Bryan, R. S.; Dobyns, J. H.; and Linscheid, R. L.:** Total elbow arthroplasty. A five-year experience at the Mayo Clinic. *J. Bone and Joint Surg.*, 63-A: 1050-1063, Sept. 1981.
19. **Müller, M. E.; Allgöwer, M.; Schneider, R.; and Willenegger, H.:** *Manual of Internal Fixation. Techniques Recommended by the AO Group.* Ed. 2. New York, Springer, 1979.