

# The Use of Topographical Landmarks to Improve the Outcome of Agee Endoscopic Carpal Tunnel Release

Tyson K. Cobb, M.D., Gary A. Knudson, M.D., and William P. Cooney, M.D.

---

**Summary:** A modified approach to endoscopic carpal tunnel release has been developed and tested in 60 cadaveric specimens by three surgeons using the Agee endoscopic carpal tunnel release system. The modified approach, which includes specific localization of the hook of the hamate, flexor retinaculum, and the superficial palmar arch utilizing topographical landmarks, avoids entry into Guyon's canal and injury to the ulnar artery and nerve, median nerve, and common digital nerves. Use of the anatomic approach resulted in significantly superior results. There were fewer incomplete releases, and fewer surgical passes were required, for the inexperienced surgeons. When these anatomic considerations were not included, the learning curve was much steeper. For surgeons planning endoscopic surgical release of the transverse carpal ligament, the described topographical approach improves the technical competence with the procedure and reduces the number of complications and learning curve associated with new procedures. We recommend the use of topographical landmarks and other anatomic considerations during endoscopic carpal tunnel release. **Key Words:** Agee—Carpal tunnel—Carpal tunnel syndrome—Endoscopic carpal tunnel release—Surgery—Techniques.

---

**E**ndoscopic carpal tunnel release is an innovative improvement of open carpal tunnel release, an already very successful operation. Although the effectiveness and patient acceptability of the conventional open carpal tunnel release are good, disability from a painful palm, cutaneous neuroma, and recurrence are reported. Endoscopic carpal tunnel release seems to result in less postoperative morbidity, improved grip strength and endurance, and minimal serious complications.

A recent multicenter study<sup>1</sup> of the Agee "inside-job" technique showed significantly improved results over those of the conventional open carpal tunnel release in regard to time to return to work, grip and pinch strengths, and amount of scar tenderness. Although

clinical reports of rates of complications and reoperation with this technique are low (0% and 2.4%, respectively, in the recent multicenter study), they remain the primary factors impeding acceptance of this technique.<sup>2</sup> Furthermore, significant rates of complications have recently been reported for inexperienced surgeons performing endoscopic carpal tunnel release.<sup>3</sup>

## BACKGROUND

We recently completed a study of relationships of the deep anatomic structures of the carpal tunnel to the surface topography.<sup>4</sup> A method of estimating the position of the proximal and distal limits of the flexor retinaculum (transverse carpal ligament) and superficial palmar arch was developed. In addition, a new technique that is accurate and reliable was devised to establish the location of the hook of the hamate, as opposed to the use of Kaplan's cardinal line.

We believe that a more in-depth understanding of the anatomic relationships of the carpal tunnel and the application of topographical landmarks to localize the

---

*From the Department of Orthopedics, Mayo Clinic and Mayo Foundation, Rochester, Minnesota, U.S.A.*

*Address correspondence and reprint requests to William P. Cooney, M.D., Department of Orthopedics, Mayo Clinic, 200 First St. SW, Rochester, MN 55905, U.S.A.*

© 1995 by the Arthroscopy Association of North America  
0749-8063/95/1102-1060\$3.00/0

palmar arch, hook of the hamate, and extent of the flexor retinaculum will improve the safety and efficacy of endoscopic carpal tunnel release. This study was conducted to test this hypothesis.

## METHODS

The Agee carpal tunnel release system (3M Health Care) was used to perform endoscopic carpal tunnel release on 60 cadaver upper extremities. The operative technique has previously been described.<sup>1</sup> We called this first description the original approach. Three participants performed 20 endoscopic carpal tunnel releases each. One participant was already very knowledgeable about the Agee technique and did not need additional training. The other two participants were residents who had no clinical experience in the use of the Agee technique. Both of the residents attended a 3M-sponsored "inside-job" surgical skills workshop and were taught the technique of single portal endoscopic release of the carpal tunnel. For this study, one resident performed the Agee approach with the aid of the new anatomic knowledge (modified technique), and the other resident, who was not knowledgeable of the anatomic guidelines, performed the original endoscopic approach.

The 60 hand specimens were randomized by number and for right and left. Each resident released the carpal tunnel in 8 right and 12 left hands. The experienced surgeon released 10 right and 10 left carpal tunnels; in this group, the original 3M approach was used on 10 specimens (5 right and 5 left) and the modified technique was used in 10 specimens (5 right and 5 left).

The time required for each procedure was recorded, as was the order of the procedure. From this information the authors assessed the effect of the modified technique on surgical time and also established learning curves. The time was started when the surgeon began to position the hand for topographical markings and was stopped when the surgeon was satisfied that the release was complete, including release of the fascia proximal to the incision. Therefore, our time differs from that of an actual operative procedure because it does not include time for instrument setup, skin closure, or surgical dressing.

During the endoscopic procedures, a single endoscopic "pass" for division of the transverse carpal ligament was recommended. Second passes with the surgical blade were done in a limited number of specimens when "incomplete" division was confirmed visually. Only intact fibers confirmed by direct visualiza-

tion with the endoscope were released. The number of passes for each procedure was recorded. All difficulties encountered by the surgeon were also recorded for each procedure.

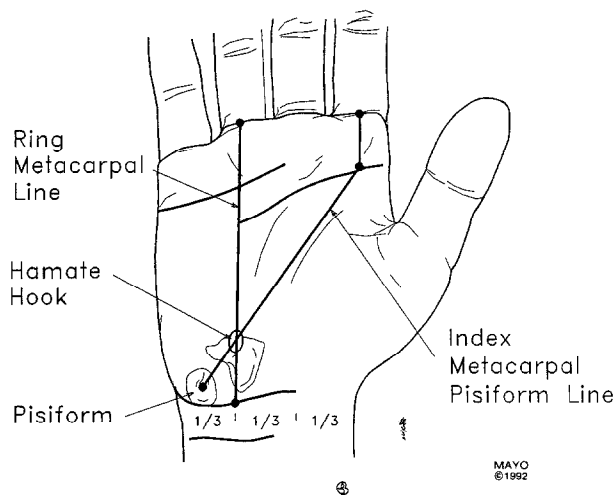
## Specimen Assessment

After completion of all 60 endoscopic carpal tunnel releases, 56 of the specimens were dissected under magnification ( $\times 2.5$ ) to determine the extent of the surgical release. For more accurate localization of the position of the incomplete release, the previously described three-segment system was used.<sup>5</sup> According to this system, the proximal segment is proximal to the pisiform and scaphoid tubercle; the middle segment lies between the pisiform and scaphoid tubercle proximally and the hamate hook and the ridge of the trapezium distally; and the distal segment lies distal to the hamate hook and ridge of trapezium. The length and position of the flexor retinaculum left intact were recorded. All complications were recorded, particularly injury to the nerves, vessels, and tendons. Because anomalous anatomy can cause difficulty with endoscopic carpal tunnel release, all anomalous anatomic findings were recorded; likewise, the relative position of the superficial palmar arch to the distal aspect of the cut flexor retinaculum was measured and recorded.

Four of the 60 specimens were frozen in liquid nitrogen and sectioned transversely on an electric band saw in 0.5-cm sections. These specimens were examined for interesting anatomic relationships and the above-noted characteristics to the extent possible.

## Modified Technique

Anatomic considerations based on the findings of a previous study<sup>4</sup> were used to devise a modified approach for endoscopic carpal tunnel release. First, the hook of the hamate was localized by drawing a line from the central aspect of the base of the ring finger to the distal flexor crease of the wrist at the junction of the ulnar and middle thirds. A second line was drawn from the proximal flexor crease of the palm in line with the central aspect of the index finger (or index metacarpal bone) to the pisiform bone. The hook of the hamate was marked at the junction of these two lines (Fig 1). Second, the estimated position of the hook of the hamate was used during the operation with respect to three important anatomic observations: (1) the distal aspect of the flexor retinaculum lies 1 cm distal to the hook of the hamate; (2) the flexor retinaculum (carpal canal) should be released just radial to this point, and the median nerve and its recurrent branch, which occupy the central or radial aspect of the canal,



**FIG 1.** Technique for estimating position of hook of hamate. One line is drawn from base of ring finger to junction of ulnar and middle thirds of distal flexor crease of wrist. A second line is drawn from proximal flexor crease of palm in line with central aspect of index finger (or index metacarpal bone) to pisiform bone. Estimated position of hook of hamate is at the junction of these two lines. (Reprinted with permission of the Mayo Foundation.<sup>4</sup>)

should be avoided; (3) a trocar passed into Guyon's canal should pass ulnar to the hook of the hamate, and the surgeon will thus be alerted of this complication; (4) the position of the superficial palmar arch should lie approximately 4.5 cm distal to the distal flexor crease of the wrist or approximately 2.5 cm distal to the hook of the hamate (Fig 2). The approximate positions of the superficial palmar arch and the distal extent of the flexor retinaculum were marked on the palm of each specimen and used as a guide during the endoscopic release.

Finally, the carpal tunnel should be entered in the middle aspect because in the distal forearm the antebrachial fascia and the proximal aspect of the flexor retinaculum are fused anteriorly (Fig 3).<sup>5</sup> On the ulnar aspect, these fascial planes separate. The ulnar artery and nerve and the tendon of the flexor carpi ulnaris lie between these two fascial planes. A probe placed between these two fascial planes (near the tendon of the flexor carpi ulnaris) will be advanced into Guyon's space, whereas a probe placed into the proximal aspect of the carpal tunnel (near the palmaris longus tendon) will be advanced into the carpal tunnel. Proper identification and incision through the antebrachial fascia are important for preventing accidental entrance into Guyon's space.

**Statistical Analysis**

Differences in time and number of passes between the two techniques were tested with the Kruskal-Wallis

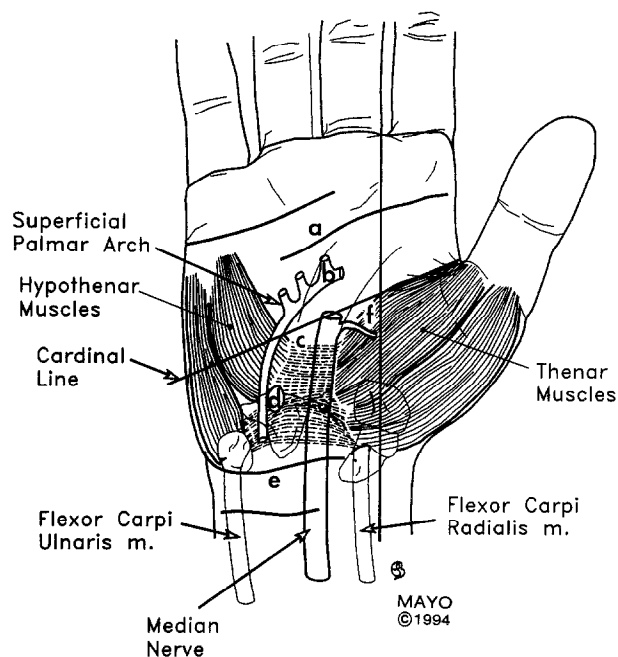
test. Analysis of variance was used to test differences in degree of release between the two techniques. *P* values < 0.05 were considered statistically significant.

**RESULTS**

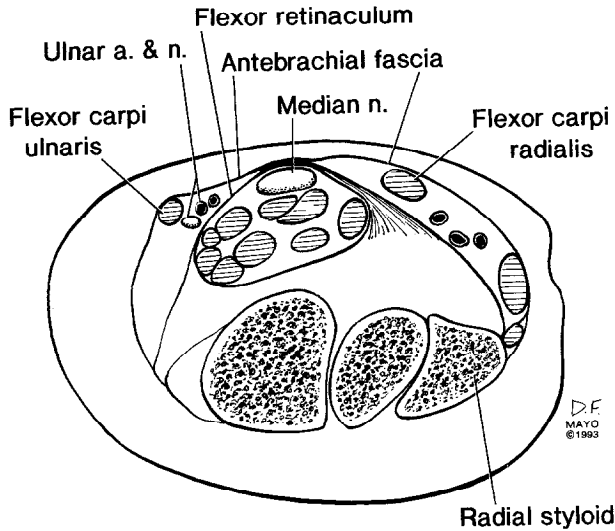
**Operating Time**

The mean operating time for the three surgeons was 6.9 minutes. For the original endoscopic approach, the mean operating time for the inexperienced surgeon was 9.55 minutes (range, 20 to 4 minutes), whereas the mean operating time for the experienced surgeon was 4.6 minutes (range, 6 to 4 minutes).

With the modified approach, the mean operating time was 6.25 minutes (range, 9 to 5 minutes) for the inexperienced surgeon and 5.4 minutes (range, 7 to 4 minutes) for the experienced surgeon. The learning curve was steeper for the resident using the original endoscopic release than for the resident using the modified approach (Fig 4). The difference in time for the inexperienced surgeons was statistically significant (*P* = .003). The difference in time for the two techniques was less than 1 minute for the experienced surgeon and was not significant (*P* > .05).



**FIG 2.** Relative position of flexor retinaculum and superficial palmar arch in relation to topographic markings. (a) Proximal palmar crease of hand; (b) superficial palmar arch; (c) distal extent of flexor retinaculum; (d) hook of hamate; (e) distal flexor crease of wrist; (f) site of entry of recurrent branch of median nerve into thenar muscles. (Modified and reprinted with permission of the Mayo Foundation.<sup>4</sup>)



**FIG 3.** Transverse section of wrist at distal radial styloid. Nine flexor tendons and median nerve are enclosed in proximal aspect of carpal tunnel. Proximal portion of flexor retinaculum is fixed to antebrachial fascia anteriorly and split medially and laterally. Note how anterior approach through antebrachial fascia in central aspect of wrist in region of palmaris longus tendon results in simultaneous section of proximal portion of flexor retinaculum and entry into proximal portion of carpal canal. A more medial approach near tendon of flexor carpi ulnaris results in entry into proximal aspect of Guyon's canal. (Modified from Cobb et al.<sup>5</sup> © American Society for Surgery of the Hand, by permission of Churchill Livingstone. Modified version copyrighted and used with permission by the Mayo Foundation.)

**Number of Passes**

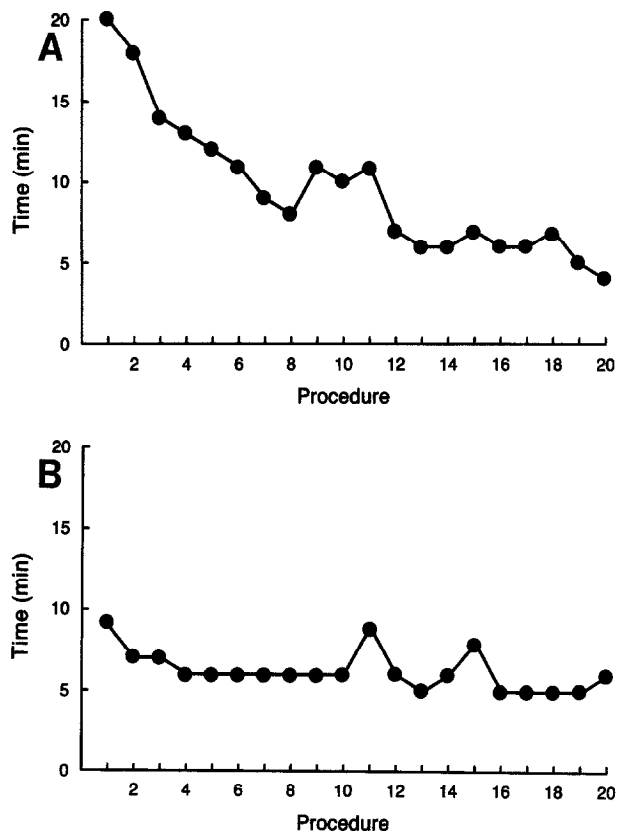
Full indiscriminant second passes were not made in any of the 60 procedures. When a second pass was performed, it was done so in a limited fashion to include only the intact fibers that were seen through the endoscope. The average number of passes with the surgical blade was 1.55 (range, 1 to 3) for the inexperienced surgeon using the traditional technique and 1.05 (range, 1 to 2) for the inexperienced surgeon using the modified technique. This difference was statistically significant ( $P = .004$ ). The mean number of passes for the staff surgeon was 1.2 (range, 1 to 2) for both techniques. More than one pass was performed by the inexperienced surgeons in 9 of 20 cases with the original technique and in 1 of 20 with the modified technique. There was no difference in the number of passes by technique for the experienced surgeon ( $P > .05$ ).

**Comments on Operative Findings**

A blunt probe was placed into Guyon's canal in two specimens by the inexperienced surgeon using the traditional technique. However, this placement was noted by the surgeon and the probe was withdrawn

and correctly positioned into the carpal canal. The inexperienced surgeon using the modified technique operated on two specimens in which he would have converted to an open procedure if in an actual surgical setting. In one of these, the canal was tight and passage of the blade assembly was difficult. The procedure in this specimen resulted in an operation time of 9 minutes (maximal time for the 20 procedures). The other difficult specimen had an abundance of synovial tissue obscuring the surgeon's view. In two procedures, the ulnar artery fell into the interval between the two borders of the sectioned flexor retinaculum after the release. This was observed after the release and, therefore, did not complicate the procedure.

The authors observed that the striated transverse nature of the flexor retinaculum was very prominent and readily apparent when it was approached extrabursally. Rubbing these fibers with the carpal tunnel probe in a proximal/distal stroking motion produced a ribbed effect that was occasionally audible. Observing this phe-



**FIG 4.** Learning curves for operating time for inexperienced surgeons using (A) the traditional technique and (B) new technique. Note steeper curve for traditional technique, which stabilized after 12 procedures, compared with less steep slope for new technique, which stabilized after three procedures.

**TABLE 1.** Degree of Carpal Tunnel Release in 60 Cadaver Specimens, by Technique

	Technique		Total No.
	Modified, No.	Traditional, No.	
Release of proximal and middle segments of the flexor retinaculum (n = 60)			
Complete	30 (100%)	30 (100%)	60 (100%)
Incomplete	0	0	0
Release of distal portion of flexor retinaculum (n = 60)			
Complete	30 (100%)	26 (87%)	56 (93%)
Incomplete	0	4 (13%)	4 (7%)
Complications (n = 56)			
Probe into Guyon's canal	0	2 (7%)	2 (3.6%)
Damaged structures	0	0	0

nomenon provided additional orientation during this procedure.

### Degree of Release

The entire proximal and middle segments of the flexor retinaculum were sectioned in all 60 procedures (Table 1). The distal (aponeurotic) portion of the flexor retinaculum<sup>5</sup> was incompletely sectioned in 4 of the 60 specimens (Fig 5). All of these incomplete sectionings occurred in the 30 procedures in which the original technique of operative planning was used. Three of these were in the procedures performed by the inexpe-

rienced surgeon using the original technique. The lengths of unsectioned fibers were 3, 4, and 5 mm for these three specimens. One incomplete release occurred in the procedures performed by the staff surgeon using the original approach. The unsectioned fibers were 4 mm in length in this specimen. Overall comparison of incomplete release with the original and modified techniques showed a statistically significantly lower probability of incomplete release with the modified technique ( $P = .04$ ).

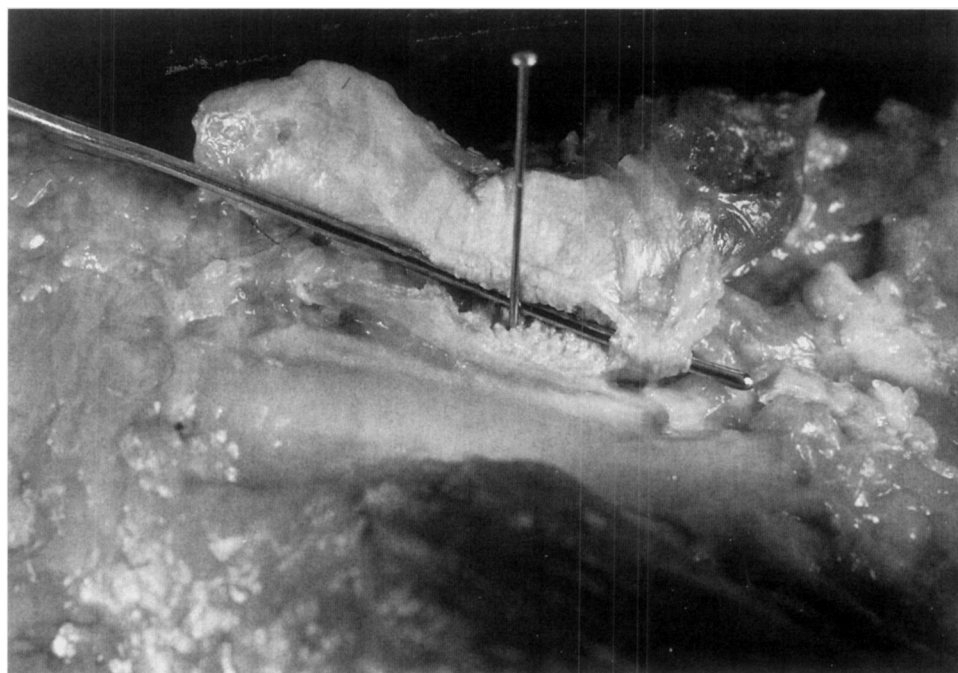
### Position of the Cut

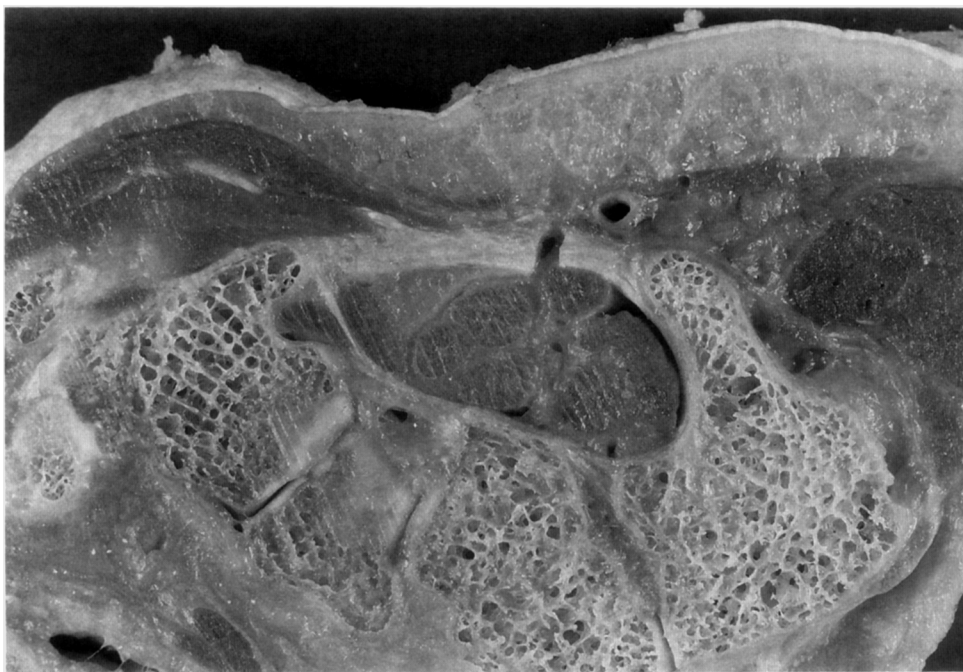The position of the blade assembly was relatively constant for all procedures. The mean distance from the hook of the hamate was 4.1 mm (range, 2 to 7 mm). The mean distance for the four groups was 4.5 mm for the inexperienced surgeon using the traditional approach (range, 2 to 7 mm), 3.7 mm for the inexperienced surgeon using the modified approach (range, 2 to 5 mm), 4.2 mm for the staff surgeon using the traditional approach (range, 3 to 7 mm), and 4.1 mm for the staff surgeon using the modified approach (range, 3 to 5 mm).

### Complications

No important structures were damaged in any of the 56 specimens dissected. The median nerve, recurrent branch of the median nerve, ulnar artery and nerve, superficial palmar arch, common digital nerves, and

**FIG 5.** Dissected specimen after endoscopic carpal tunnel release. Flexor retinaculum has been detached from radial side of carpal tunnel and reflected to ulnar side, exposing distal surface of flexor retinaculum. Probe was placed in defect created by endoscopic carpal tunnel release. Note that probe passes anterior to a 4-mm segment of distal (aponeurotic) portion of flexor retinaculum (incomplete release). The pin marks distal aspect of hook of hamate. The proximal and middle segments of the flexor retinaculum have been completely sectioned in this specimen. Left, proximal; right, distal; bottom, radial; top, ulnar.





**FIG 6.** Axial section at level of hamate hook. Note ulnar artery lies radial to hamate hook.

tendons were examined in all 56 dissections and found to be intact.

### ANATOMIC VARIATIONS

#### Position of Superficial Palmar Arch

There was a great degree of variation in the position of the superficial palmar arch relative to the distal extent of the cut flexor retinaculum. The mean distance for the 56 dissected specimens was 12.5 mm (range, 2 to 26 mm) from the distal edge of the transverse carpal ligament, or approximately 2 cm from the hook of the hamate. The distance was 5 mm or more in 93% of the specimens and 10 mm or more in 73% of the specimens.

In most of the specimens, the ulnar artery gave off a proximal retinacular branch and a distal retinacular branch. These branches coursed transversely across the palmar aspect of the carpal canal between the volar carpal ligament (and palmaris brevis muscle) and flexor retinaculum. In several specimens, these branches were well developed. None of these vessels were injured in any of the specimens. The ulnar artery was noted to be radial to the hook of the hamate in several specimens (Fig 6). The exact frequency of this variation cannot be determined from this study because it is more difficult to confirm on gross dissections than on cross-sectional analysis. A double superficial pal-

mar arch was noted in one specimen. Abnormal origins of hypothenar muscles that extended across the distal aspect of the flexor retinaculum were seen in one specimen.

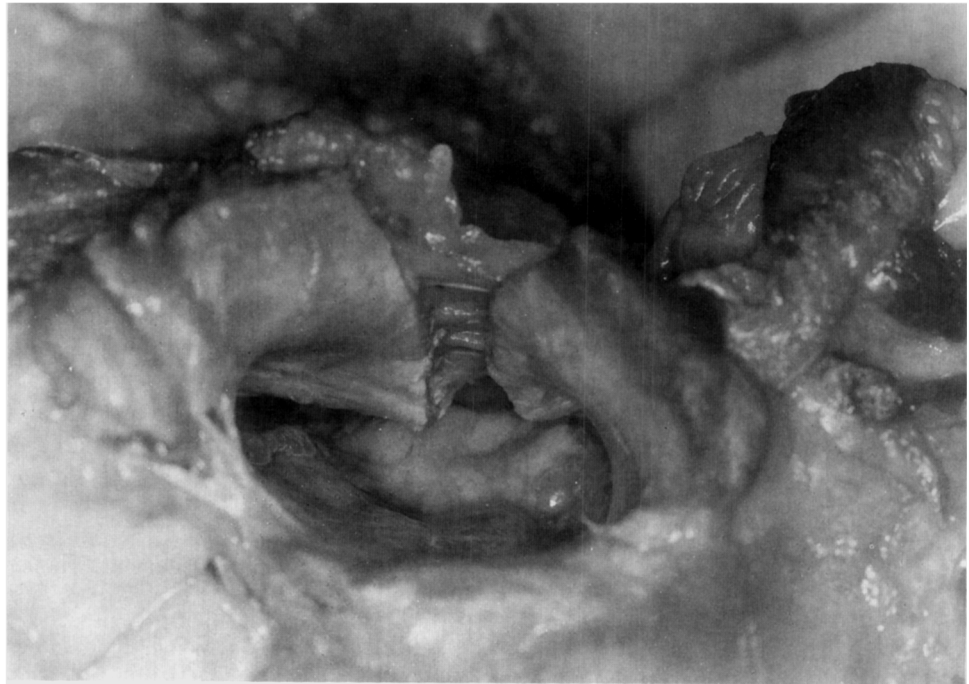The median nerve and two common digital nerves were scarred to the dorsal surface of the flexor retinaculum in one specimen, and muscle tendon junctions from flexor superficialis tendons had abnormally long extension of muscle tissue into the canal in several specimens. These findings did not affect the endoscopic procedure or cause complications.

### DISCUSSION

Open operation for carpal tunnel syndrome has remained the accepted standard of care for many years. Nevertheless, reductions in postoperative pain and time away from the workplace are strong motivational forces for endoscopic carpal tunnel release procedures. The awareness of the general public has increased such that patients may ask about the safety and efficacy of this procedure or even specify that they prefer this method. Advising such a patient on the basis of publications to date is a difficult task because of mixed and varied reports.

In a recent cadaver study<sup>6</sup> in which the two-portal technique was used, incomplete releases occurred in 50% of 24 specimens. In the incomplete releases, 39%

**FIG 7.** Dissected specimen after endoscopic carpal tunnel release. Specimen has been disarticulated at radiocarpal joint. Carpal bones are at bottom of photograph. View is into carpal tunnel from proximal to distal. Note that superficial fibers of thenar and hypothenar muscles are intact but do not prevent widening of carpal arch, as shown by interval between cut surfaces of flexor retinaculum.



(range, 9% to 100%) of the ligament was left intact. Five specimens had intact distal fibers that were 8.2 mm (range, 2 to 15 mm) in length. Six specimens had incomplete release of the central portion of the ligament. Release of Guyon's canal occurred in one specimen, the ulnar artery was lacerated in one specimen, and sectioning of the periosteum of the hook of the hamate without release of the transverse carpal ligament occurred in one specimen. In another cadaver study of the two-portal technique, 9 of 24 specimens (38%) had an incomplete release.<sup>3</sup> Complications occurred in 4 of the 24 specimens (17%), including ulnar artery laceration, fracture of the hook of the hamate, complete division of the median nerve, and partial laceration of a flexor tendon. Only 12 of the 24 specimens (50%) had complete release without complication.

The findings in our cadaver study were significantly different from those reported by others. There were no neurovascular injuries in the current study. Furthermore, complete release of the true transverse carpal ligament (middle segment of flexor retinaculum bounded by pisiform, scaphoid tubercle, hamate hook, and ridge of trapezium) occurred in all 60 procedures. In four (6.7%) specimens, the distal segment of the flexor retinaculum (aponeurotic portion) was incompletely released. The average length of incomplete release was 4 mm (range, 3 to 5 mm). Although differences in terminology prevent exact comparisons

with the study by Lee et al,<sup>6</sup> it appears that the true transverse carpal ligament (middle segment of flexor retinaculum) was incompletely released in six specimens (25%) and the distal aponeurotic portion was left intact in five specimens (21%) in their study. The clinical significance of an incomplete release of the distal aponeurotic fibers has not been studied and is unknown.

Fibers of origin of the thenar and hypothenar muscles extend over the transverse carpal ligament in most cases. In our experience, these fibers are often not disturbed or are minimally disturbed by the Agee system. Some intact fibers were found in 96.4% of the specimens in our study, and 66% had at least 1 cm of these fibers present. This feature may allow for the improved grip strength noted with this technique compared with open procedures. These fibers do not appear to limit widening of the carpal arch (Fig 7) but should help minimize bowstringing of the flexor tendons in addition to maintaining grip and pinch strength. These fibers also protect the ulnar artery during the release. For this reason, it is clear that the relatively short blade of the Agee device helps to prevent ulnar artery lacerations.

The blade assembly for the Agee device places the surgical blade approximately 4 mm from the hook of the hamate when correctly positioned against the hook of the hamate. This position prevents the previously

reported complication of incomplete release due to release of periosteum of the hook of the hamate.<sup>6</sup>

Regarding the ulnar artery and superficial palmar arch, it is of interest that the arch is routinely depicted as having an extreme ulnar base with a wide horseshoe-type arch. This anatomic arrangement is not commonly encountered in our experience; rather, there is a gentle curve in the radial direction often following a path just to the ulnar side of a line drawn from the hook of the hamate to the metacarpal head of the index ray. The ulnar artery may course radial to the hook of the hamate and can be close to the surgical blade during endoscopic carpal tunnel release. The ulnar artery appears to be highly mobile and surrounded by fat, which serves to protect it. However, it can be at risk in certain patients. For this reason we do not recommend the use of external digital pressure on the palm during endoscopic carpal tunnel release. External pressure may compress and decrease the mobility of the ulnar artery and cause injury.

Although the mean operating times were statistically different for the inexperienced surgeons, they may not be clinically significant. However, the differences in the learning curves are clinically significant (Fig 2). The relatively lengthy operating times for the early procedures represent a significant degree of uncertainty as to where to make the distal forearm fascial incision and at what level distally to begin the distal release of the flexor retinaculum. Topographical markings provide reference points that enhance proper placement of the surgical blade for the distal release. The 13% rate of incomplete release of the distal fibers for the original technique compared with no incomplete releases of the distal fibers for the 30 procedures in which the modified technique was used stresses the importance of topographical landmarks. The learning curve can be minimized when the recommended topographical landmarks described in this study are followed.

Accidental entry into Guyon's canal with probes or other instruments can be avoided by entering the antebrachial fascia in the central aspect of the wrist where it is fused to the proximal portion of the flexor retinaculum (Fig 3). In our study, probes were placed into Guyon's canal in two specimens. Both incidents occurred in the procedures performed by the inexperienced surgeon who was not using the modified anatomic approach. This complication did not occur when the modified technique was used.

For surgeons with minimal experience, the anatomic approach reduces the number of incomplete releases, decreases the learning curve, and prevents accidental entry into Guyon's canal. We recommend the use of topographical landmarks and other anatomic considerations described herein during endoscopic carpal tunnel release.

**Acknowledgment:** The authors thank Duane M. Ilstrup and Steven L. Wallrichs, Section of Biostatistics, for assistance with statistical analysis and Dean R. Fisher, Department of Anatomy, for help with cadaveric specimens.

## REFERENCES

1. Agee JM, McCarroll HR Jr, Tortosa RD, Berry DA, Szabo RM, Peimer CA. Endoscopic release of the carpal tunnel: a randomized prospective multicenter study. *J Hand Surg Am* 1992;17:987-995.
2. Brown RA, Gelberman RH, Seiler JG III, Abrahamsson SO, Weiland AJ, Urbaniak JR, Schoenfeld DA, et al. Carpal tunnel release: A prospective randomized assessment of open and endoscopic methods. *J Bone Joint Surg Am* 1993;75:1265-1275.
3. Rowland E, Kleinert JM. Endoscopic carpal-tunnel release in cadavers: An investigation of the results of twelve surgeons with this training model. *J Bone Joint Surg Am* 1994;76:266-268.
4. Cobb TK, Cooney WP, An K-N. Relationship of deep structures of the hand and wrist to topographical landmarks. *Clin Anat* 1993;6:300-307.
5. Cobb TK, Dalley BK, Posteraro RH, Lewis RC. Anatomy of the flexor retinaculum. *J Hand Surg Am* 1993;18:91-99.
6. Lee DH, Masear VR, Meyer RD, Stevens DM, Colgin S. Endoscopic carpal tunnel release: A cadaveric study. *J Hand Surg Am* 1992;17:1003-1008.