

# New Frontiers in Hand Arthroscopy

Tyson K. Cobb, MD<sup>a,\*</sup>, Stacey H. Berner, MD<sup>b</sup>,  
Alejandro Badia, MD<sup>c</sup>

## KEYWORDS

- Small joint arthroscopy • Trapeziometacarpal arthroscopy
- Thumb carpometacarpal arthroscopy
- Metacarpophalangeal arthroscopy
- Proximal interphalangeal joint arthroscopy
- Pisotriquetral joint arthroscopy
- Distal interphalangeal joint arthroscopic arthrodesis
- Metacarpophalangeal joint

This article covers new and emerging techniques in small joint arthroscopy in the hand. Recent improvement in the quality of small joint scopes and advancement in techniques have allowed for many new small joint arthroscopic procedures in the hand. The arthroscopic classification for thumb carpometacarpal (CMC) arthritis as well as treatment of each stage are covered. Findings for arthroscopic treatment of pantrapezial arthrosis are reviewed. Metacarpophalangeal (MCP) arthroscopy for the treatment of synovitis, arthritis, fractures, and gamekeeper injuries is discussed, as is arthroscopy of the proximal interphalangeal (PIP), pisotriquetral (PT), fourth and fifth CMC, and distal interphalangeal (DIP) joints.

## ARTHROSCOPIC STAGING OF THUMB CMC JOINT

Arthroscopy allows for a true assessment of the joint status. Although thumb CMC arthritis has traditionally been staged by simple radiographic means,<sup>1</sup> this does not represent an accurate assessment of articular status. This observation is particularly true in the early stages of osteoarthritis, when symptoms are frequently worse than

the radiographs suggest; an arthroscopic joint evaluation depicts the process.<sup>2</sup>

In arthroscopic stage I there is a diffuse synovitis but with minimal, if any, articular cartilage wear. Ligamentous laxity, particularly the volar ligaments, is a frequent finding. If the patient presents early enough, an arthroscopic synovectomy can be performed, using a full-radius resector and a radiofrequency probe, followed by shrinkage capsulorrhaphy if capsular redundancy is present. The joint is then protected in a thumb spica cast for several weeks depending on the extent of capsular laxity. A greater degree of joint instability requires a more aggressive capsulorrhaphy and longer immobilization to achieve joint stability and slow the progression of articular cartilage degeneration.

In arthroscopic stage II there is focal wear of the articular surface on the central to dorsal aspect of the trapezium and the deep palmar aspect of the metacarpal base. This situation does suggest that a progressive arthritic process is under way and requires a joint modifying procedure to alter the biomechanics of the joint. After an arthroscopic synovectomy, debridement, and frequent loose body removal, the joint is evaluated for any instability or laxity. A shrinkage thermal capsulorrhaphy

---

The authors have nothing to disclose.

<sup>a</sup> Orthopaedic Specialists, Davenport, IA, USA

<sup>b</sup> Advanced Centers for Orthopaedic Surgery and Sports Medicine, 10 Crossroads Drive Suite 210, Owings Mills, MD 21117, USA

<sup>c</sup> Badia Hand to Shoulder Center, Miami, FL, USA

\* Corresponding author.

E-mail address: [tysoncobbmd@gmail.com](mailto:tysoncobbmd@gmail.com)

Hand Clin 27 (2011) 383–394

doi:[10.1016/j.hcl.2011.06.004](https://doi.org/10.1016/j.hcl.2011.06.004)

0749-0712/11/\$ – see front matter © 2011 Elsevier Inc. All rights reserved.

is performed in many cases. The arthroscope is then removed and one of the portals is extended distally to approach the metacarpal base. A dorsoradial closing wedge osteotomy, akin to Wilson's original technique,<sup>3</sup> is then performed to place the thumb in an extended and abducted position.<sup>4</sup> This procedure is to minimize the tendency for metacarpal subluxation and to change the contact points of the worn articular cartilage, effectively centralizing the metacarpal. The osteotomy is usually stabilized by a single oblique K-wire that is also placed across the first CMC joint. Pinning allows for healing of the osteotomy in the correct position but also corrects the metacarpal subluxation that is often seen in this critical stage. Correction of the subluxation may arrest the arthritic process but there are no data to support this. A thumb spica cast protects the metacarpal during healing and the wire is removed 5 to 6 weeks after the operation. An arthroscopic staging is used to determine the ideal indications for this osteotomy, because it is difficult to determine which joints have early focal trapezial wear by any imaging modality. Metacarpal osteotomy has had good results in past studies, including a more recent paper by Tomaino.<sup>5</sup> Late follow-up of these patients has confirmed that the metacarpal remains centralized. The role of capsular shrinkage versus the alteration of force vectors by the use of osteotomy likely both play a role in changing the joint biomechanics.

In arthroscopic stage III there is diffuse trapezial articular cartilage loss. The metacarpal base may also show significant cartilage loss to varying degrees. The arthroscopic findings indicate that this is not a joint that is salvageable and a simple debridement or osteotomy does not provide an acceptable long-term result. An arthroscopic partial trapeziectomy is then performed by burring away the remaining articular cartilage and removing the subchondral bone down to a bleeding surface. This procedure functions not only to increase the joint space but to allow for cancellous bone bleeding, which forms a thrombus, becoming a fibrous tissue interposition. One might augment this procedure by inserting an interposition material, although superior results have not been proven with interposition.

Stage III can also be treated by a traditional open excisional arthroplasty, arthrodesis, or total joint replacement depending on surgeon preference. However, it has been our experience that the minimally invasive nature of arthroscopic resection arthroplasty has largely obviated open surgery, which is inherently more painful, more complication ridden, and limits future options.

Although arthroscopic management of Badia stage 1, 2, and 3 is an acceptable standard for many surgeons, patients with pantrapezial arthrosis have traditionally been treated with open procedures. Recently we have completed a study of 35 cases of arthroscopic resection arthroplasty performed at the scaphotrapeziotrapezoidal (STT) joint and the CMC for pantrapezial arthrosis with good results.<sup>6</sup>

### **Indications**

Surgical indications include pain localized at both the CMC and STT joints, radiographic changes consistent with arthrosis, and full-thickness widespread cartilage loss of both joints found at the time of arthroscopy.

### **Contraindications**

Contraindications include active infection and instability in patients who desire correction. In the authors' experience most patients are satisfied with pain relief despite persistent instability at the CMC and MCP joints.

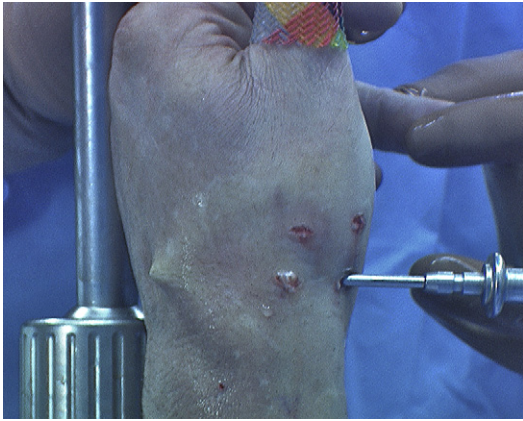
### **Surgical Technique**

The arm is suspended using 2.3 to 4.5 kg (5–10 pounds) of finger-trap traction on only the thumb. When indicated, diagnostic arthroscopy is performed with a 1.9-mm arthroscope. An arthroscopic resection arthroplasty is performed using a 2.3-mm or 2.7-mm arthroscope. Volar (1R) and dorsal (1U) portals are used for CMC arthroscopy. STT arthroscopy is performed through volar (1R) and dorsal (1U) portals, which are placed approximately 1 cm proximal to the corresponding CMC portals. An additional dorsal portal is used when necessary by placing a blunt probe through the volar portal across the STT or CMC joint and out the dorsum of the hand (**Fig. 1**).

Two to 3 mm of bone is removed from each side of both the CMC and STT joints with a 3.0-mm or 4.0-mm barrel bur (**Fig. 2**). Graft Jacket (Wright Medical Technology Inc, Arlington, TN, USA) was used as interposition material in 23 of the cases. The patients are typically immobilized for 1 to 3 weeks. The current protocol includes a postoperative splint for 1 week followed by a removable hand-based Orthoplast splint.

Preoperative data collected included a 2-point self-reported pain scale, disabilities of arm, shoulder and hand (DASH) outcome measure, range of motion, grip strength, and pinch strength.

Pain score (0–10) improved from 7 (range 5–10) preoperatively to 1 (range 0–6) at 1 year postoperatively ( $P < .0005$ ) (**Fig. 3**). DASH score improved from 46 preoperatively to 19 at 1 year (**Fig. 4**).

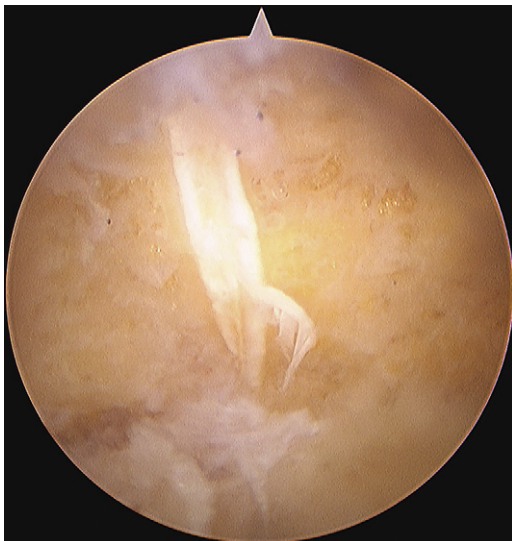

**Fig. 1.** Pantrapezial arthroscopy: portal access across STT and CMC.

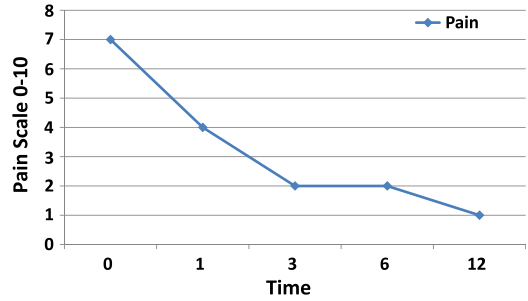
Thumb range of motion did not change significantly. All but one patient reached the base of the fifth digit at 1-year follow-up. The mean improvement in key pinch was 1.3 kg (2.9 pounds) (95% confidence interval [CI] 0.84–5.00) ( $P = .0008$ ). The mean improvement in grip strength was 4.3 kg (9.52 pounds) (95% CI 1.467–17.56) ( $P = .023$ ).

**Complications**

Two patients developed postoperative infections. One was superficial and resolved with outpatient antibiotics, and 1 deep infection required arthroscopic irrigation and debridement. Three patients developed a flexor carpi radialis tendonitis, 2 of which resolved with conservative treatment and



**Fig. 2.** Arthroscopic view of the distal aspect of the STT joint following arthroscopic resection.



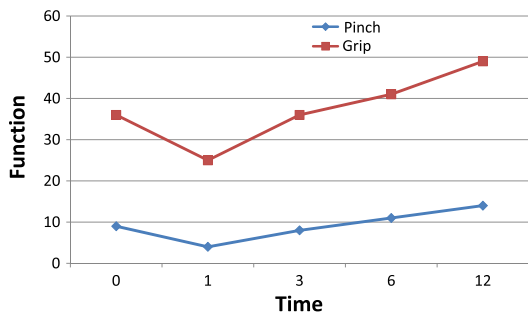
**Fig. 3.** Pantrapezial arthroscopy: pain score improvement from preoperatively to 1 year postoperatively.

1 of which required surgical release. Two patients with persistent pain underwent open revision surgery. Five patients reported paresthesias in the distribution of the superficial branch of the radial nerve, all of which resolved by the third postoperative month.

**MCP ARTHROSCOPY**

The MCP joint is ideally suited for arthroscopic evaluation and treatment.<sup>7–10</sup> The neurovascular structures are not close to the arthroscopic portals. The bony and tendinous landmarks are generally easy to identify. The MCP joint represents a single compartment. Therefore, visualization and navigation of the joint are easily accomplished with a short learning curve. The indications, equipment, and technique associated with MCP arthroscopy are discussed in the next sections, supported with clinical case examples.

MCP arthroscopy is a useful diagnostic and therapeutic entity. There are several reports in the rheumatology literature of diagnostic staging of inflammatory arthropathy.<sup>11–16</sup> Synovectomy may be a useful adjunct in this patient population as well, with short-term improvement in symptoms. However, long-term benefits have not yet been established.<sup>14</sup> In addition, debridement, removal of loose bodies, and chondroplasty can be useful



**Fig. 4.** Pantrapezial arthroscopy: pinch and grip from pre-operatively to 1 year postoperatively.

in the posttraumatic setting.<sup>10</sup> Minimally invasive lavage and debridement can be performed in selected cases of intra-articular sepsis.

Arthroscopy can be useful for assessment and treatment of fractures, dislocations, and ligament injuries. Intra-articular fractures can be treated by arthroscopic and arthroscopically assisted means. Adequacy of reduction of the articular surface can be readily verified arthroscopically. Successful reduction of Stener lesions and arthroscopically assisted repair of collateral ligament injuries of the ulnar collateral ligament (UCL) of the thumb MCP joint have been reported within the literature.<sup>17-22</sup>

Expanded applications include arthrofibrectomy and arthroscopically assisted arthrodiesis of thumb MCP joints. Current analysis of the feasibility of arthroscopically assisted arthroplasty may hold promise for the future.<sup>7</sup>

#### Equipment:

- Small joint arthroscope
- Traction apparatus
- Fluid management system
- Motorized shaver
- Small joint punch, grasper, biopsy forceps.

#### Optional:

- Currettes/osteotomes
- Fluoroscopy unit
- Wire driver
- Suture anchors
- Radiofrequency probe
- Headless screws.

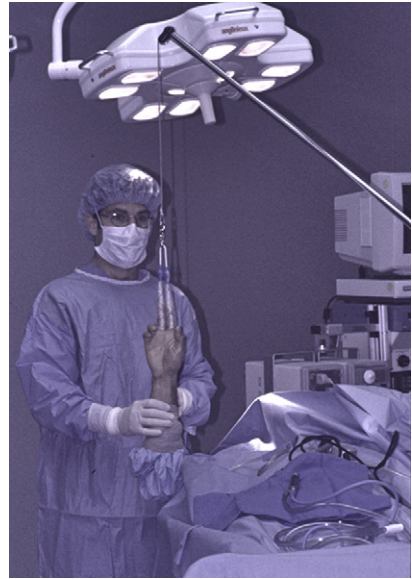Review of the literature reveals reports using various sizes and types of arthroscopes. The 1.0-mm needle arthroscope has been used for biopsy and staging procedures.<sup>11,13</sup> More commonly, the 1.7-mm, 1.9-mm, 2.0-mm, and 2.3-mm devices are used.<sup>7,12,14,18</sup> The authors' preference is a 1.9-mm, 30° arthroscope.

Various commercial traction tower devices are available. An overhead T-bar device (**Fig. 5**), is described in the technique section.

Normal saline or lactated Ringer solution can be used, at the surgeon's preference. An arthroscopic fluid pump can facilitate fluid management, provided that a low-pressure setting is used.

### Technique

The patient is placed in the supine position and general or regional anesthesia is established. A pneumatic tourniquet is placed around the brachium of the operative extremity and an arm holder is applied. The arm holder attaches to the operating room bed and provides countertraction. An overhead T-bar is applied to the bed, directly



**Fig. 5.** MCP: scope set-up.

opposite the operative extremity. The hand and arm are prepared and draped in routine sterile fashion. A sterile finger trap is applied to the operative digit or thumb, and then attached to a hook on the T-bar. Sterile finger-trap application can be aided by the application of tincture of benzoin or Mastisol to the involved digit. Alternatively, a K-wire may be inserted through the digit and finger trap to prevent slippage of the trap.<sup>18</sup> Weights are suspended from the opposite end of the pulley system in the T-bar. Traction of 4.5 kg (10 pounds) is applied through an overhead adjustable T-bar (see **Fig. 5**).

Radial and ulnar MCP portals are localized with the aid of 2 18-gauge needles (**Figs. 6 and 7**).

Fluoroscopic guidance may be used to assist in adequate identification of the joint space. The portals are established after distending the joint with 0.5% Marcaine or 0.9% normal saline solution. The radial and ulnar portals are each located off the midline, in the region of the sagittal hood fibers, in the interval between the collateral ligaments and the extensor tendon. In the digits the tubercles at the base of the proximal phalanges can be palpated and these represent the insertion points of the collateral ligaments. The extensor tendon is not violated. The skin is lanced and blunt dissection is performed until the joint capsule is encountered. A blunt arthroscopic trochar and cannula are inserted into the joint. The trochar is removed and the 1.9-mm, 30° arthroscope is placed in the MCP joint. Fluid inflow is through the arthroscope. An intravenous pressure bag is



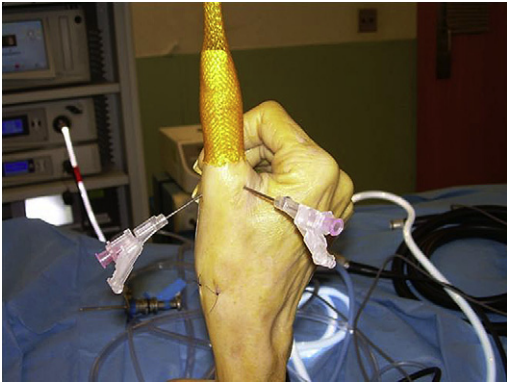


Fig. 6. MCP: portal localization.

applied to a 1-L bag of sterile 0.9% normal saline solution at 100 mm Hg. The pressure bag serves as a pump. Viewing and instrumentation portals are alternated. Small joint biopsy punches and graspers may be used. Debridement and synovectomy are performed with a 2.0-mm full-radius resector blade. Osteocartilagenous loose bodies are removed when encountered. A radiofrequency probe may be helpful to perform synovectomy and debridement, but care should be taken to provide adequate flow so as to avoid generating high temperatures in this low-volume joint. A monopolar probe may be preferable in this regard. Microcurrettes, elevators, and osteotomes may be useful for clearing debris, and performing manipulation of fragments during treatment of fractures. K-wires can be used as joysticks to assist in fracture reduction and may be used for provisional or definitive fracture fixation. Headless screws can be useful for treating large articular fracture fragments. These screws can be inserted percutaneously with arthroscopic and fluoroscopic guidance. Minisuture or microsuture anchors may be required for ligament repair.

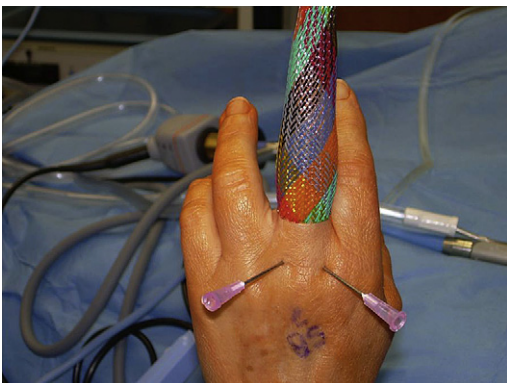


Fig. 7. MCP: portal localization.

## Procedures and Illustrative Cases

### Inflammatory arthropathy

Arthroscopy can be useful for staging and treatment of inflammatory arthropathy.<sup>11–16,19,20</sup> Synovectomy can be performed with a motorized shaver or a radiofrequency device. Maintenance of constant, but low-level inflow pressure provides adequate distention, because hypertrophic synovium may obscure visualization. Adequate inflow decreases the possibility of thermal damage to cartilage and soft tissue structures when using a radiofrequency device. Compared with alternative imaging modalities, arthroscopy provides more precise information regarding the status of the articular cartilage, and this may aid in planning future procedures.<sup>20</sup> Reports of synovectomy have shown good short-term results, although the literature does not report maintenance of the short-term benefits over the long-term.<sup>14,20</sup> Therefore, it seems that the usefulness of MCP arthroscopy for inflammatory arthropathy is to aid in diagnosis through synovial biopsy, as well as for staging of articular cartilage involvement. A short-term palliative benefit has also been shown with synovectomy (Figs. 8 and 9).

### Degenerative arthritis/cartilage lesions

Isolated cartilage lesions and early degenerative arthritis can be assessed, staged, and treated arthroscopically. Debridement of loose cartilage and chondroplasty has been reported in the literature. Good intermediate-term results have been noted with chondroplasty for isolated full-thickness cartilage lesions (Figs. 10 and 11).<sup>10</sup>

However, there are no established guidelines outlining a treatment algorithm for degenerative arthritis.

### Removal of loose bodies

Similar to larger joints, loose body removal can be performed on the MCP joints of the digits and the thumb (Figs. 12 and 13). The unicompartamental nature of the joint facilitates localization and removal of loose bodies. The minimally invasive approach is preferable, because it permits rapid return to activity by obviating incision in the extensor expansion and capsulotomy.

### Intra-articular fractures

Fractures involving the articular surfaces and supporting subchondral bone of the MCP joint can be assessed, and treated with an arthroscopically assisted approach (Figs. 14–16). K-wires may be used as joysticks to assist reduction, and can also be used for definitive fixation. Alternatively, small conventional screws or headless screws

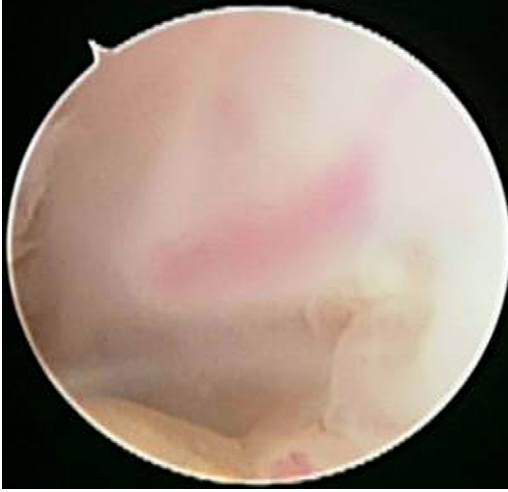


Fig. 8. MCP: inflammatory arthropathy preoperatively.

can be used based on surgeon preference and fracture pattern.

#### ***Collateral ligament repair***

Ligament injuries in the digits and thumb can be treated with arthroscopically assisted repair. In the thumb, reduction of Stener lesions and joint stabilization has been reported for the treatment of acute unstable UCL injuries (Figs. 17 and 18).<sup>17</sup>

The thumb MCP joint is ideally suited for arthroscopically assisted arthrodesis. For individuals with widespread cartilage loss, or with gross instability, fusion may be indicated. Arthroscopic preparation of the joint surfaces and percutaneous cannulated screw fixation are a minimally invasive alternative to open arthrodesis.

The MCP joint of the thumb is ideally suited for arthroscopically assisted fusion. However,

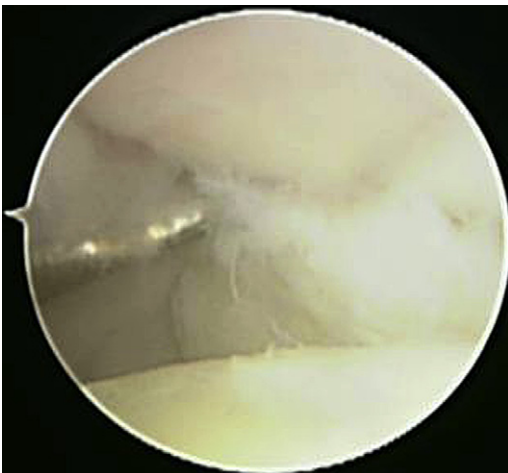


Fig. 9. MCP: inflammatory arthropathy postoperatively.

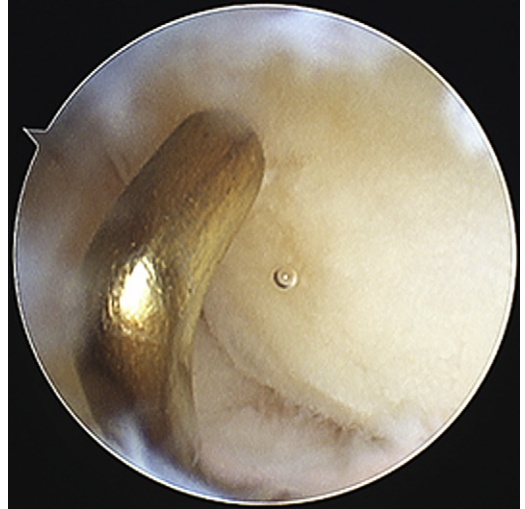

Fig. 10. MCP: after traumatic cartilage lesion.

maintenance of mobility is of paramount importance for the MCP joints of the digits. Arthroscopically assisted joint resurfacing may be of benefit for the digits. Arthroscopic evaluation and assistance in preparation of the joint surface for osteochondral transplant can be performed and may play an expanded role in the treatment of isolated articular cartilage defects. In vitro analysis of arthroscopically assisted joint surface preparation for insertion of synthetic or denatured allograft material is under way; this technique may hold great promise for the future and further study, including in vivo analysis, is warranted.

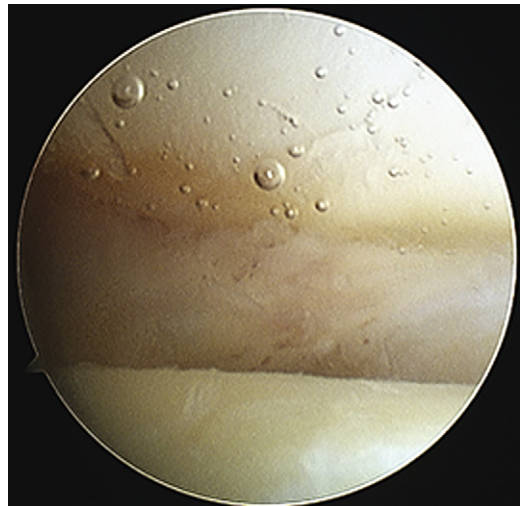


Fig. 11. MCP: after traumatic cartilage lesion after chondroplasty.

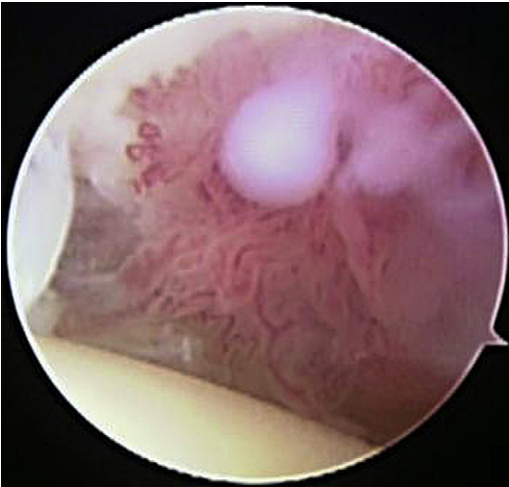


Fig. 12. MCP: loose body.

### Summary of MCP Joint Arthroscopy

The MCP joint is ideally suited for arthroscopic evaluation and treatment. Nonetheless, the paucity of information in the literature suggests that operative arthroscopy of the MCP joints remains less commonly performed when compared with other joints in the upper extremity such as the wrist, elbow, and shoulder. Further awareness and study will likely expand the application of arthroscopy to surgery to the MCP joints.

### PT ARTHROSCOPY

Pisotriquetral arthroscopy is a novel, yet seldom indicated procedure that makes the gee-whiz list. It is indicated for persistent, painful PT joint arthrosis unresponsive to conservative care. PT

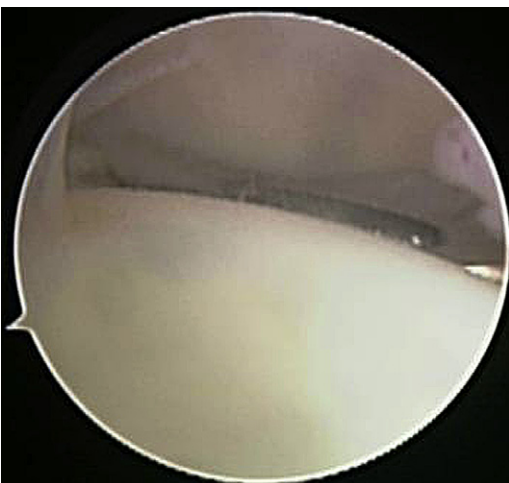


Fig. 13. MCP: after removal of loose body.

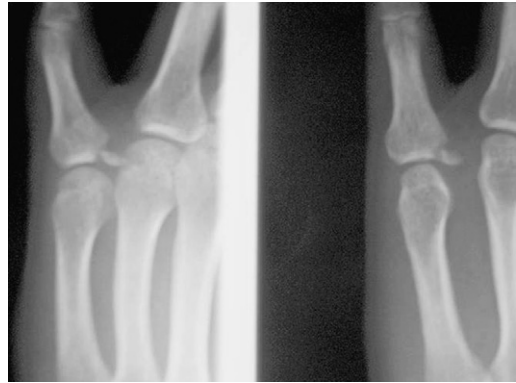

Fig. 14. MCP: articular fracture.

arthroscopy is also useful for synovectomy, irrigation debridement of septic joints, arthrodesis, or loose body removal.<sup>23</sup>

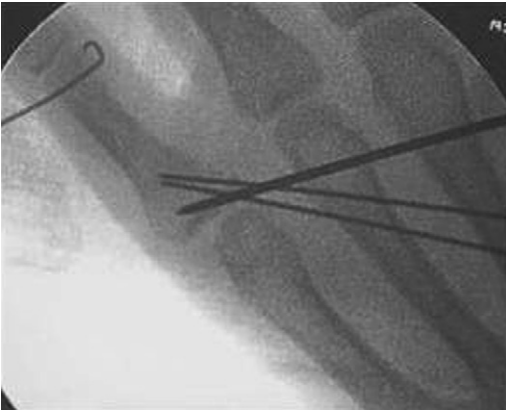
The hand is suspended by finger-trap traction for convenience of positioning. Two portals are localized with 18-gauge needles under fluoroscopy (Fig. 19). Both are placed ulnar to the PT joint, one proximal and one distal. Access to the PT joint can be obtained via the 6R wrist portal in some patients.<sup>24</sup> From the 6R portal, the arthroscope is directed ulnarly, volarly, and distally. Access depends on the presence or absence of a membrane separating the PT joint from the wrist joint. Membrane, if present, can be debrided for entry into the PT joint. However, we prefer direct entry from the ulnar portals.

Incisions are made through the skin. A small, blunt hemostat is used to gain entrance into the PT joint. A 1.9-mm, 30° arthroscope and a 2-mm

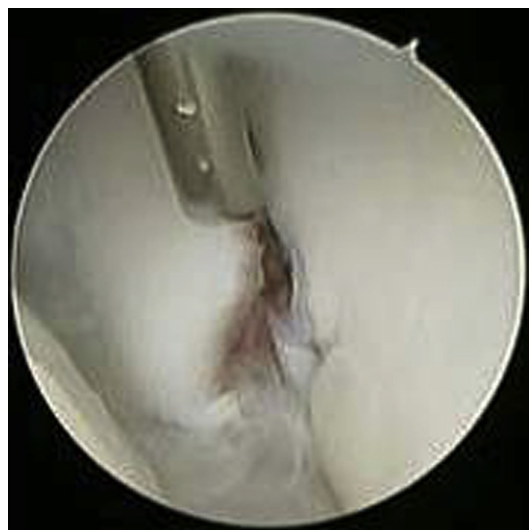

Fig. 15. MCP: arthroscopic reduction.





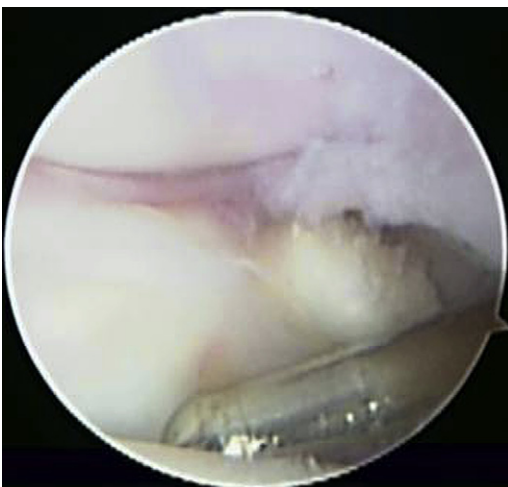
**Fig. 16.** MCP: arthroscopically assisted percutaneous reduction.

shaver are used to perform synovectomy and clear the joint of debris. A 2-mm bur is used to remove 2 mm of bone from the pisiform and triquetrum (**Fig. 20**). The portals are closed with Steri-Strips after the procedure. A short-arm splint is used for 1 week.

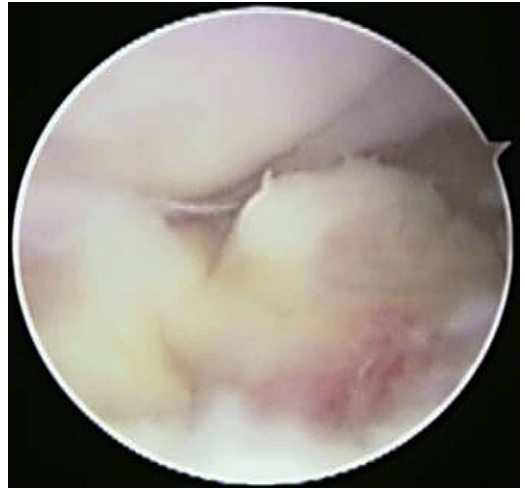### **Illustrative Case**

A 57-year-old woman presented with a several-year history of ulnar-sided wrist/hand pain. She had pain with palpation over the PT joint. PT arthritis was noted on the plane film, and a bone scan showed uptake at the PT joint. She had immediate relief of pain with an injection of local anesthetic into the PT joint under fluoroscopic control. A cortisone injection of the PT joint gave only temporary relief of pain.

A diagnostic injection test has to be interpreted with some caution and in context with other



**Fig. 17.** MCP: chronic UCL tear.



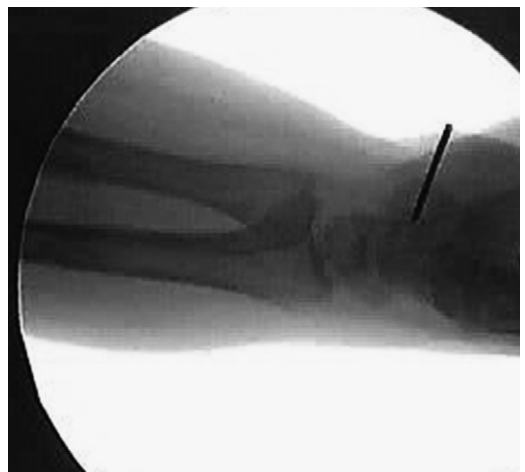**Fig. 18.** MCP: UCL after debridement and mobilization.

findings of the workup because many patients do not have a membrane separating the PT joint from the radiocarpal joint.<sup>24</sup> Therefore, a local anesthetic injection into the PT joint may anesthetize and therefore eliminate pain from adjacent areas of the wrist.

Full-thickness, widespread cartilage loss was noted at the time of arthroscopy (**Fig. 21**). Arthroscopic resection arthroplasty of PT joint was performed. Two years after arthroscopic resection arthroplasty, she remained essentially pain free.

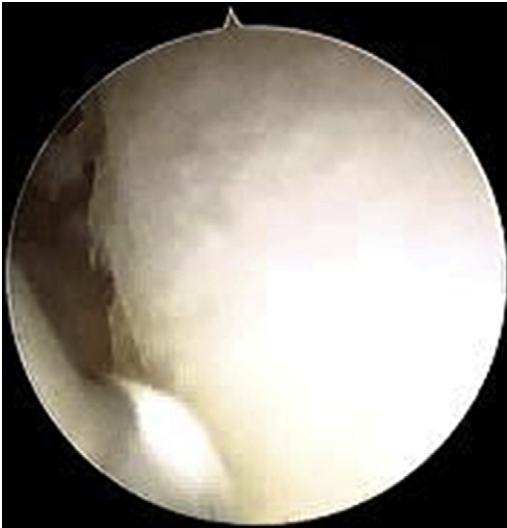
### **PIP ARTHROSCOPY**

Arthroscopy of the PIP joint has limited usefulness. The indication for arthroscopy of the PIP joint



**Fig. 19.** PT: portal fluoroscopy.





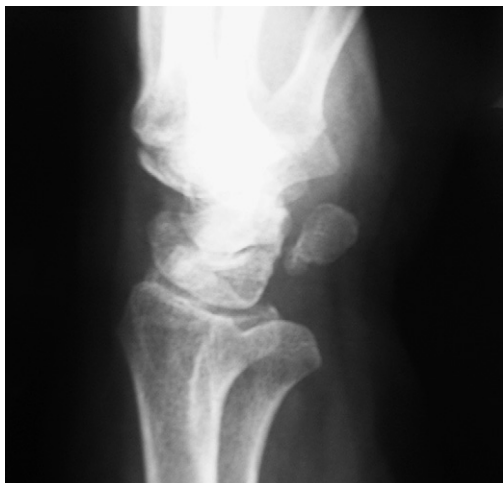**Fig. 20.** PT: bur removal of 2 mm of pisiform and triquetrum.

includes synovectomy, irrigation debridement of a septic joint, loose body removal, or diagnostic/staging purposes.<sup>25</sup>

Contraindications include an active cellulitis or severe scarring or contracture of the dorsal tissue secondary to injury or burn.

The authors prefer the use of portals between the lateral bands and collateral ligaments. Portals between the central slip and the lateral bands have also been described.<sup>26</sup>

The digit can be positioned vertically with finger-trap traction or horizontally with manual traction. Because the PIP is a tight bicondylar joint, access to the volar aspect of the joint is limited. Therefore, horizontal positioning allows for joint flexion



**Fig. 21.** PT: cartilage loss noted during arthroscopy.

and improved access. General or regional anesthesia may be used with either brachial or digital tourniquet.

The joint is distended with saline, and a 3-mm to 4-mm incision is made over the desired portals. Portals can be localized with an 18-gauge needle and fluoroscopy. Blunt spreading with small hemostat allows access into the joint. A tapered blunt trocar is used, and flow is provided through the cannula. The authors use a 1.9-mm, 30° arthroscope (**Fig. 22**). Synovectomy is performed with a 2-mm shaver (**Fig. 23**). Portals are closed with Steri-Strips after the procedure. Early motion is encouraged after synovectomy.

#### FOURTH AND FIFTH CMC ARTHROSCOPY

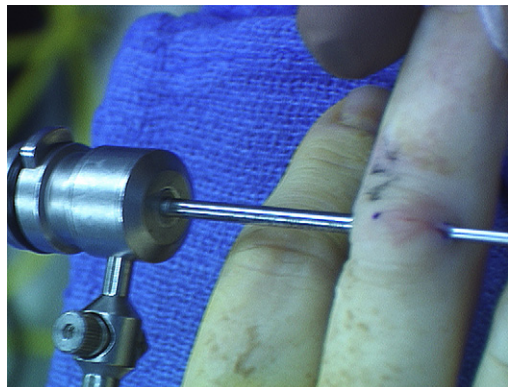
The fourth and fifth CMC joints are amenable to arthroscopic evaluation. Usefulness and indications have not been established.

The hand is suspended by finger traps on the fourth and fifth digits with 4.5 kg (10 pounds) of traction. An ulnar portal is localized with an 18-gauge needle and fluoroscopy. The fifth CMC joint is easily viewed arthroscopically through a direct ulnar portal. A dorsal portal is localized with an 18-gauge needle under fluoroscopy (**Fig. 24**). This portal is used for a working portal. A 2-mm shaver is used for synovectomy.

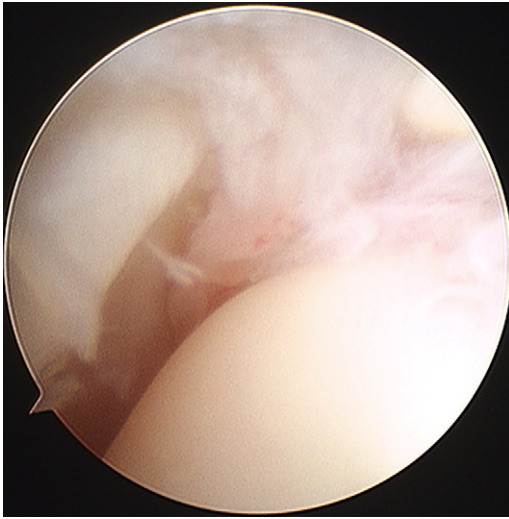
The author uses a 1.9-mm, 30° arthroscope. With the arthroscope in the ulnar portal, the arthroscope can then be transitioned to view across the fifth CMC and into the fourth CMC.

#### DIP

Arthrodesis of the DIP joint of the fingers or interphalangeal joint of the thumb is an effective surgical treatment of painful arthrosis. The headless screw has been shown to be a safe and effective alternative for fixation with open arthrodesis

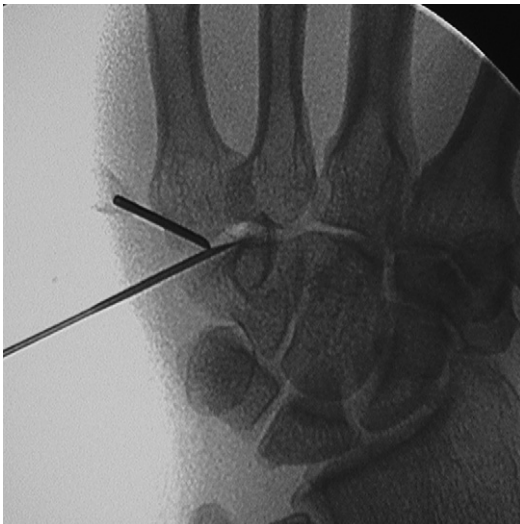

**Fig. 22.** PIP: 1.9-mm, 30° arthroscope.



**Fig. 23.** PIP: synovectomy performed with 2-mm shaver.

techniques.<sup>27–29</sup> Arthroscopic arthrodesis of the DIP joint of the fingers or interphalangeal joint of the thumb is indicated for pain, deformity, or instability. Common causes include degenerative or posttraumatic arthritis, chronic mallet finger, and chronic flexor digitorum profundus injury. This is a technically challenging procedure and should be reserved for only very experienced arthroscopists. The learning curve is steep and the risk of scope damage is high. Contraindications include active infection, bony geometry too small to allow for safe placement of headless screws, and lack



**Fig. 24.** 5th CMC Arthroscopic portals localized under fluoroscopy.



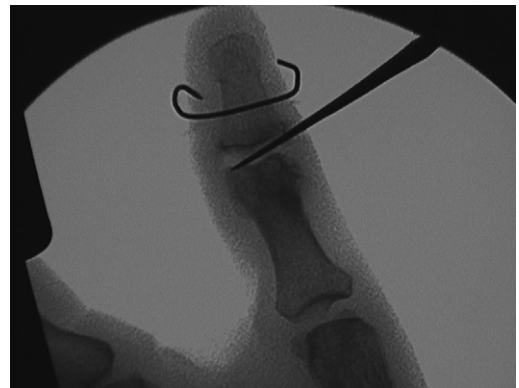
**Fig. 25.** DIP: digit suspended in finger-trap traction.

of equipment or experience to safely perform procedure.

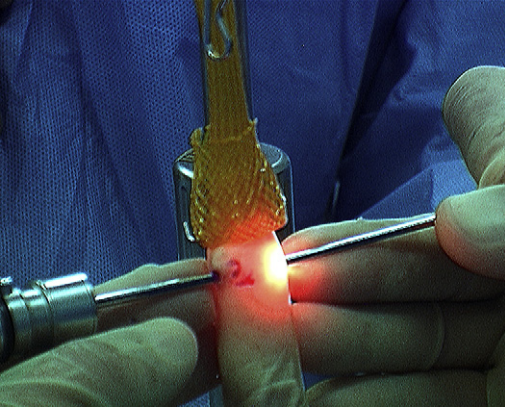
### ***Surgical Technique***

The digit is suspended with finger-trap traction (**Fig. 25**). This traction is accomplished by turning a standard disposable finger trap inside out to double the wall. It is then placed over the distal phalanx and secured with a transverse 0.35 K-wire through the distal phalanx. The procedure can be performed with a digital or brachial tourniquet. General or regional anesthesia can be used. Traction of 2.3 to 4.5 kg (5–10 pounds) is applied.

Eighteen-gauge needles are used to localize the medial and lateral joint lines under fluoroscopy. Longitudinal incisions are placed over the medial and lateral sides of the joint, 5 to 6 mm long.



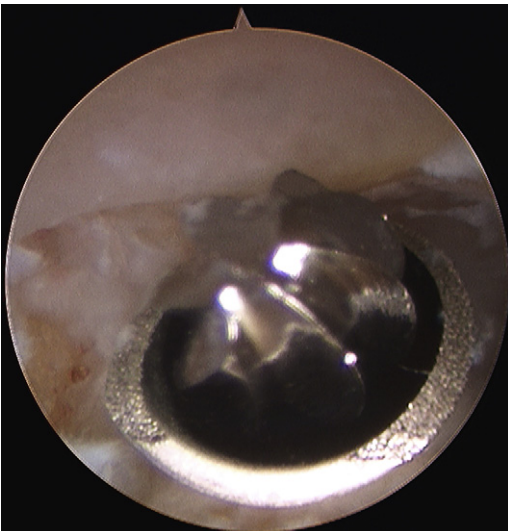
**Fig. 26.** DIP: collateral ligaments released with number 69 Beaver blade.



**Fig. 27.** DIP: joint is opened with Freer elevator.

The collateral ligaments are released with a number 69 Beaver blade. The joint is opened enough to create a working space with a Freer elevator (**Fig. 26**). A 1.9-mm arthroscope is inserted in 1 side of the joint, and a 2.5-mm shaver is inserted in the opposite side of the joint (**Fig. 27**). The joint is cleared of debris. The scope and shaver are then switched, and the opposite side of the joint is cleared of debris, allowing for visualization of both sides of the joint.

Next a 2-mm hooded bur is brought into the joint and 1 to 2 mm of bone is removed from the proximal and distal sides of the joint (**Fig. 28**). Only one-half of the medial and lateral dimensions of the joints are burred to minimize arthroscope damage. The scope and the bur are then switched, and the other side of the joint is burred down to bleeding



**Fig. 28.** DIP: 1.9-mm arthroscope inserted in 1 side of joint, 2.5-mm shaver on another.

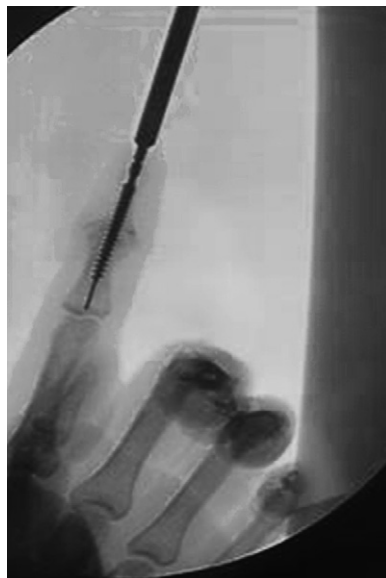subchondral bone. Care must be taken not to damage the scope because the working space is limited. Dorsal osteophytes can be removed by palpating the osteophyte under the dorsal capsule and carefully working the bur along the dorsal margin of the joint. The amount of bone resection is assessed visually through the scope and also with the aid of fluoroscopy. If dorsal osteophytes are large, a small flat rasp can be placed dorsally under the extensor tendon for removal.

After resection of the joint the finger trap and transverse fixation wire are removed. A longitudinal guide wire is then placed in the central axis under fluoroscopic control. A cannulated drill is used to drill across the DIP joint followed by placement of the screw (**Fig. 29**).

The authors prefer the mini Acutrak screw because it is small enough to minimize the chance of nail bed damage. The guidewire is then removed. Portals are closed with Steri-Strips. A bulky dressing is applied with a splint for 7 to 10 days. A removable splint is then used for protection as needed, based on patient comfort, for 4 weeks. MCP and PIP joints are mobilized immediately after surgery. Clinical healing occurs at about 6 weeks, with radiographic healing at approximately 8 weeks.<sup>30</sup>

### Complications

Complications include nonunion, nail bed injury, and infection.<sup>28</sup> One case was complicated by partial thickness skin loss secondary to fluid



**Fig. 29.** DIP: 2-mm hooded bur removes bone from joint.



infiltration.<sup>30</sup> This complication resolved by the second week postoperatively without additional treatment. Medial and lateral approaches place the digital nerves at risk. Care should be taken to avoid injury to these structures.

## REFERENCES

- Eaton RG, Glickel SZ. Trapeziometacarpal osteoarthritis. Staging as a rationale for treatment. *Hand Clin* 1987;3:455-71.
- Badia A. Trapeziometacarpal arthroscopy: a classification and treatment algorithm. *Hand Clinics* 2006;22(2):153-63.
- Wilson J. Osteotomy of the first metacarpal in the treatment of arthritis of the carpometacarpal joint of the thumb. *Brit J Surg* 1973;60:854-8.
- Badia A, Khachandani P. Treatment of early basal joint arthritis using a combined arthroscopic debridement and metacarpal osteotomy. *Tech Hand Up Extrem Surg* 2007;11(2):168-73.
- Tomaino MM. Treatment of Eaton stage I trapeziometacarpal disease. Ligament reconstruction or thumb metacarpal extension osteotomy? *Hand Clin* 2001;17:197-205.
- Cobb T, Sterbank P, Lemke J. Arthroscopic resection arthroplasty for treatment of combined carpometacarpal and scaphotrapezotrapezoid (pantrapezial) arthritis. *J Hand Surg* 2011;36(3):413-9.
- Berner SH. Metacarpophalangeal arthroscopy: techniques and applications. *Metacarpophalangeal joint arthroscopy-techniques and applications. Tech Hand Up Extrem Surg* 2008;12(4):208-15.
- Chen YC. Arthroscopy of the wrist and finger joints. *Orthop Clin North Am* 1979;10:723-33.
- Rozmaryn L, Wei N. Metacarpophalangeal arthroscopy. *Arthroscopy* 1999;15(3):333-7.
- Vaupel G, Andrews J. Diagnostic and operative arthroscopy of the thumb metacarpophalangeal joint: a case report. *Am J Sports Med* 1985;13(2):139-41.
- Gaspar L, Szekanecz Z, Dezso B, et al. Technique of synovial biopsy of the metacarpophalangeal joint using the needle arthroscope. *Knee Surg Sports Traumatol Arthrosc* 2003;11:50-2.
- Kraan M, Reece R, Smeets T, et al. Comparison of synovial tissues from the knee joints and the small joints of rheumatoid arthritis patients: implications for pathogenesis and evaluation of treatment. *Arthritis Rheum* 2002;46(8):2034-8.
- Ostendorf B, Dann P, Wedekind F, et al. Miniarthroscopy of the metacarpophalangeal joints in rheumatoid arthritis. Rating of diagnostic value in synovitis staging and efficiency of synovial biopsy. *J Rheumatol* 1999;26:1901-8.
- Wilkes LL. Arthroscopic synovectomy in the rheumatoid metacarpophalangeal joint. *J Med Assoc Ga* 1987;76:638-9.
- Ostendorf B, Peters R, Dann P, et al. Magnetic resonance imaging and miniarthroscopy of metacarpophalangeal joints: sensitive detection of morphologic changes in rheumatoid arthritis. *Arthritis Rheum* 2001;44(11):2492-502.
- Sekiya I, Kobayashi M, Taneda Y, et al. Arthroscopy of the proximal interphalangeal and metacarpophalangeal joints in rheumatoid hands. *Arthroscopy* 2002;18(3):292-7.
- Ryu J, Fagan R. Arthroscopic treatment of acute complete thumb metacarpophalangeal ulnar collateral ligament tears. *J Hand Surg Am* 1995;20:1037-42.
- Slade J III, Gutow A. Arthroscopy of the metacarpophalangeal joint. *Hand Clin* 1999;15(3):501-26.
- Declercq G, Schmitgen G, Vestreken J. Arthroscopic treatment of metacarpophalangeal arthropathy in haemochromatosis. *J Hand Surg* 1994;19(2):212-4.
- Wei N, Delauter SK, Erlichman MS, et al. Arthroscopic synovectomy of the metacarpophalangeal joint in refractory rheumatoid arthritis: a technique. *Arthroscopy* 1999;15(3):265-8.
- Badia A. Arthroscopic reduction and internal fixation of bony gamekeeper's thumb. Tips and techniques. *Orthopedics* 2006;29(8):675-8.
- Badia A. Arthroscopy of the trapeziometacarpal and metacarpophalangeal joints. *J Hand Surg Am* 2007;32(5):707-24.
- Katolik LI. Arthroscopic resection, pisotriquetral joint loose body: a case report. *J Hand Surg Am* 2008;32(2):2006-9.
- Aroya AP, Aulshreshtha R, Kakarala GK, et al. Visualization of pisotriquetral joint through standard portals for arthroscopy of the wrist: a clinical and anatomical study. *J Bone Joint Surg Br* 2007;89(2):202-5.
- Sekya I, Kobayashi M, Okamoto H, et al. Arthroscopic synovectomy metacarpophalangeal and proximal interphalangeal joint. *Tech Hand Up Extrem Surg* 2008;12(4):221-5.
- Thomsen MO, Mielsen MS, Gorgensen U, et al. Arthroscopy of the proximal interphalangeal joints and fingers. *J Hand Surg Br* 2002;27:253-5.
- Leibovic SJ. Instructional course lecture. Arthrodesis of the interphalangeal joints with headless compression screws. *J Hand Surg Am* 2007;32(7):1113-9.
- Brutus JP, Palmer AK, Mosher JF, et al. Use of a headless compression screw for distal interphalangeal joint arthrodesis in digits: clinical outcome and review of complications. *J Hand Surg Am* 2006;31(1):85-9.
- Tuttle HG, Olvey SP, Stern P. Tendon avulsion injuries of the distal phalanx. *Clin Orthop Relat* 2006;445:157-68.
- Cobb TK. Arthroscopic distal interphalangeal joint arthrodesis. *Tech Hand Up Extrem Surg* 2008;12(4):266-9.